UNIVERSITÄT LEIPZIG
Medizinische Fakultät

Universitätsklinikum Leipzig
Medizin ist unsere Berufung.

Kontaminierte Herzklappen:
Anwendungen für die Krankenhaushygiene

Judith Kikhney
Institut für Medizinische Mikrobiologie und Virologie
Nationales Konsiliarlabor *Tropheryma whipplei*
MoKi Analytics GmbH | Moter Diagnostics

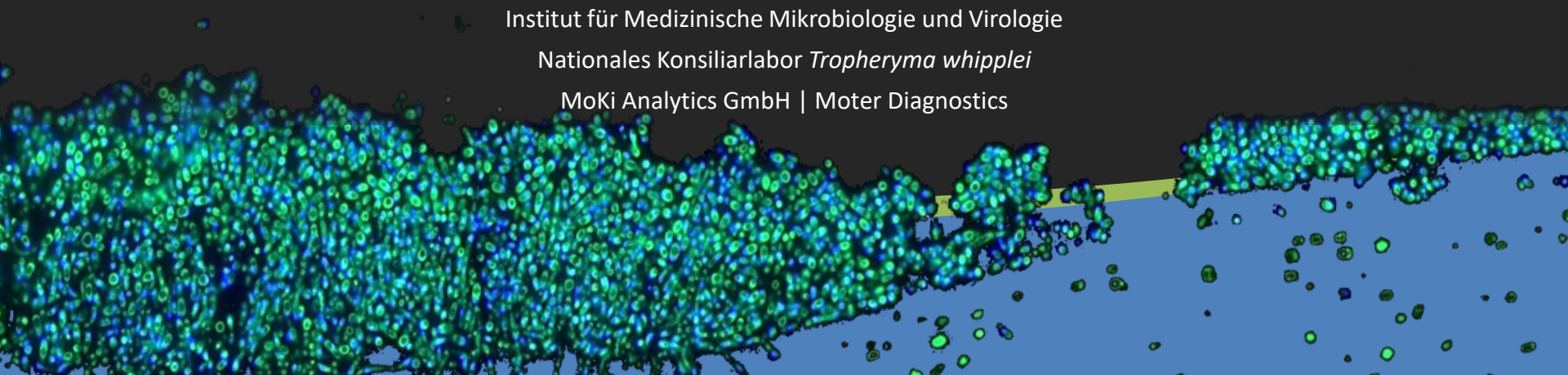

Mycobacterium chelonae associated with cardiovascular bioprostheses: An interdisciplinary effort

Biofilmzentrum/FISH Team, Charité Berlin	• Annette Moter, Laura Kursawe, Kurosh Sarbandi
Charité Berlin	• Solveigh Wiesener, Miriam Songa Stegemann, Frieder Pfäfflin, Petra Gastmeier, Volker Düsterhöft, Volkmar Falk
BfArM, Bonn, Germany	• Josef Zündorf, Beate Häuser, Esther Patricia Cónsul Tejero
Nat. Referenzzentrum Mycobacteria, Borstel	• Inna Friesen, Doris Hillemann, Martin Kuhns
LaborBerlin, Berlin	• Dinah von Schöning
PathoTres, Berlin	• Christoph Loddenkemper
Paulinenkrankenhaus Berlin	• Frank-Rainer Klefisch
Robert Koch-Institut, Berlin	• Sebastian Haller, Anja von Laer, Tim Eckmanns
Reference Center Mycobacteria, Paris	• Emmanuelle Cambau
Uni Zürich, Switzerland	• Barbara Hasse
Uni Basel, Switzerland	• Sarah Tschudin-Sutter
UKSH, Kiel, Germany	• Anette Friedrichs, Bernd Panholzer
Klinik Bogenhausen, Munich, Germany	• Walter Eichinger

Lancet Microbe 2025

All three cases BioIntegral

No.	Patient	Implantation	Explantation	FISH Team FISHseq	Nat. Reference Lab, Borstel	LaborBerlin Inna Friesen D v. Schöning
1	40y, male conduit	1/2017	12/2020 **4 years**	*M. chelonae* complex	*M. chelonae* confirmed	Auramin/Kinyoun positive
2	27y, female tricuspid valve	6/2021	10/2021 **3.5 months**	*M. chelonae* complex	*M. chelonae* confirmed	n.d.
3	52y, male aortic valve	2/2022	2/2022 **12 days**	*M. chelonae* complex	*M. chelonae* confirmed	Auramin/Kinyoun positive NGS: *M. chelonae* complex

Fluorescence in situ hybridization = FISH

Fixation → Embedding → Sectioning → FISH → Microscopy → Document.













Intra-OP Fixation







Clinic

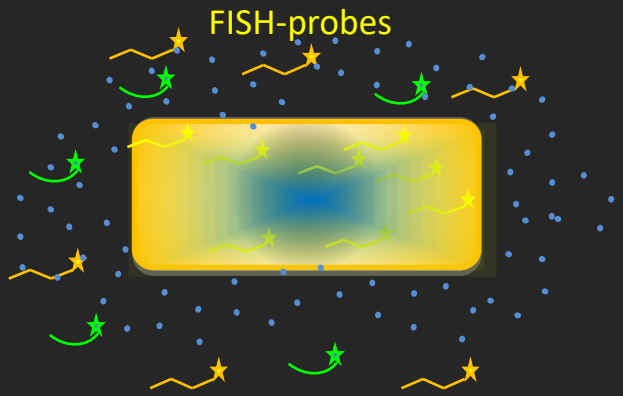

FISHseq

Routine accreditated

Fixation → Embedding

FISH → Microscopy → Dokumentation

DNA → 16S rRNA PCR → Sequencing

T A T C
G G A T
C A C G
G C C

Identification

Localisation

Biofilm?

Activity



Therapy?

yes / no?

antibiotics?

dose/duration?

Clinic

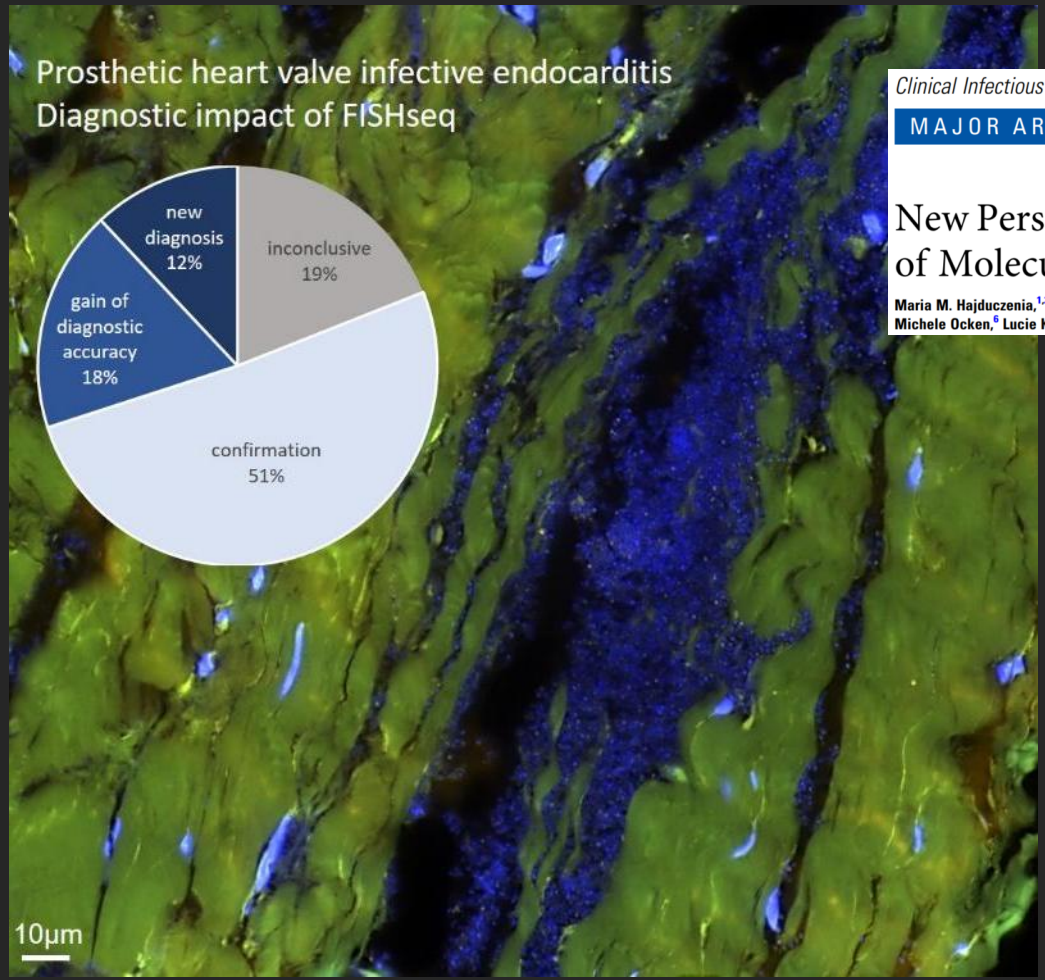

Clinical Infectious Diseases
MAJOR ARTICLE
IDSA Infectious Diseases Society of America
hivma hiv medicine association
OXFORD

New Perspectives for Prosthetic Valve Endocarditis: Impact of Molecular Imaging by FISHseq Diagnostics

Maria M. Hajduczenia,[1,2] Frank R. Klefisch,[3] Alexander G. M. Hopf,[1] Herko Grubitzsch,[4,a] Miriam S. Stegemann,[5,a] Frieder Pfäfflin,[5,a] Birgit Puhlmann,[6] Michele Ocken,[6] Lucie Kretzler,[7,a] Dinah von Schöning,[8,a] Volkmar Falk,[4] Annette Moter,[1,9,10,a] and Judith Kikhney[1,9,a,]

To the paper:

IDSA Infectious Diseases Society of America | hivma hiv medicine association | OXFORD

Clinical Infectious Diseases

VIEWPOINTS ARTICLE

The 2023 Duke-ISCVID Criteria for Infective Endocarditis: Updating the Modified Duke Criteria

Vance G. Fowler, Jr[1,2*], David T. Durack[1], Christine Selton-Suty[3], Eugene Athan[4], Arnold S. Bayer[5], Anna Lisa Chamis[1], Anders Dahl[6], Louis DiBernardo[1], Emanuele Durante-Mangoni[7], Xavier Duval[8], Claudio Fortes[9], Emil Fosbol[10], Margaret M. Hannan[11], Barbara Hasse[12], Bruno Hoen[13], Adolf W. Karchmer[14], Carlos A. Mestres[15], Cathy A. Petti[1,16], María Nazarena Pizzi[17], Stephen D. Preston[18], Albert Roque[19], Francois Vandenesch[20], Jan T. M. van der Meer[21], Thomas W. van der Vaart[21], and Jose M. Miro[22,23]

MANUSCRIPT

To the paper:

ESC European Society of Cardiology

European Heart Journal (2023) **00**, 1–95
https://doi.org/10.1093/eurheartj/ehad193

ESC GUIDELINES

2023 ESC Guidelines for the management of endocarditis

Developed by the task force on the management of endocarditis of the European Society of Cardiology (ESC)

Endorsed by the European Association for Cardio-Thoracic Surgery (EACTS) and the European Association of Nuclear Medicine (EANM)

To the paper:

All three cases BioIntegral

No	Patient	Implantation	Explantation	FISH Team FISHseq	Nat. Reference Lab, Borstel	LaborBerlin Inna Friesen D v. Schöning
1 ✓ reported	40y, male conduit	1/2017	12/2020 (4 years)	*M. chelonae* complex	*M. chelonae* confirmed	Auramin/Kinyoun positive
2 ✓	27y, female Tricuspid valve	6/2021	10/2021 (3.5 months)	*M. chelonae* complex	*M. chelonae* confirmed	n.d.
3 ✓	52Y, male Aortic valve	2/2022	2/2022 (12 days)	*M. chelonae* complex	*M. chelonae* confirmed	Auramin/Kinyoun positive NGS: *M. chelonae* complex
A	Unused valve			*M. chelonae* complex	*M. chelonae* confirmed	
B	Unused valve			*M. chelonae* complex	*M. chelonae* confirmed	

Journal of Infection (2010) 60, 467–473

ELSEVIER

BRITISH INFECTION SOCIETY

www.elsevierhealth.com/journals/jinf

UNIVERSITÄT LEIPZIG
Medizinische Fakultät

Universitätsklinikum Leipzig
Medizin ist unsere Berufung.

Mycobacterium chelonae valve endocarditis resulting from contaminated biological prostheses

T.M.V. Strabelli [a], Rinaldo Focaccia Siciliano [a,*], Jussara Bianchi Castelli [a], L.M.M.F. Demarchi [a], Sylvia Cardoso Leão [b], Cristina Viana-Niero [b], Kozue Miyashiro [c], Roney Orismar Sampaio [a], Max Grinberg [a], David Everson Uip [a]

[a] *Heart Institute (InCor), Hospital das Clínicas da Faculdade de Medicina da Universidade de São Paulo, Braz*
[b] *Department of Microbiology, Immunology and Parasitology, Universidade Federal de Sao Paulo, Brazil*
[c] *Instituto Fleury, São Paulo, Brazil*

MAJOR ARTICLE

Open Forum Infect Dis. 2015 Apr 2;2(2):

Nontuberculous Mycobacteria: An Underestimated Cause of Bioprosthetic Valve Infective Endocarditis

Coralie Bouchiat,[1] Julien Saison,[2] Sandrine Boisset,[1] Jean-Pierre Flandrois,[3] Bertrand Issartel,[4] Olivier Dauwalder,[1] Yvonne Benito,[1] Sophie Jarraud,[1] Jacqueline Grando,[5] Andre Boibieux,[2] Oana Dumitrescu,[6] François Delahaye,[7] Fadi Farhat,[8] Françoise Thivolet-Bejui,[9] Jean-Philippe Frieh,[10,11] and François Vandenesch[1]

[1]Laboratoire de Bactériologie, Centre de Biologie Est, Hospices Civils de Lyon, Bron, [2]Maladies Infectieuses, Hospices Civils de Lyon, [3]Laboratoire de Biometrie et Biologie Evolutive, Université Lyon 1-CNRS UMR 5558, Bâtiment Mendel, Villeurbanne, [4]Maladies Infectieuses, Clinique du Tonkin, Villeurbanne, [5]Unité d'Hygiène et d'Épidémiologie, Hospices Civils de Lyon, Bron, [6]Laboratoire de Bactériologie, Centre Hospitalier Lyon Sud, Hospices Civils de Lyon, Pierre-Bénite, [7]Service de Cardiologie, Hôpital Louis Pradel, Hospices Civils de Lyon, Bron, [8]Service de Chirurgie Cardiaque, Hôpital Louis Pradel, Hospices Civils de Lyon, Bron, [9]Service d'Anatomo-Pathologie, Centre de Biologie Est, Hôpital Louis Pradel, Hospices Civils de Lyon, Bron, [10]Service de Chirurgie Cardiaque, Clinique du Tonkin, Villeurbanne, and [11]Service de Chirurgie Cardiaque, Infirmerie Protestante, Caluire-et-Cuire, France

Conclusions. The body of evidence confirmed the diagnosis of prosthetic IE. The statistically significant association between bioprosthetic valves and NTM IE encourages systematic Ziehl-Neelsen staining of explanted bioprosthetic valves in case of early bioprosthesis dysfunction, even without an obvious sign of IE. In addition, we strongly question the cardiac bioprosthesis conditioning process after animal sacrifice.

Originally packaged heart valve 1

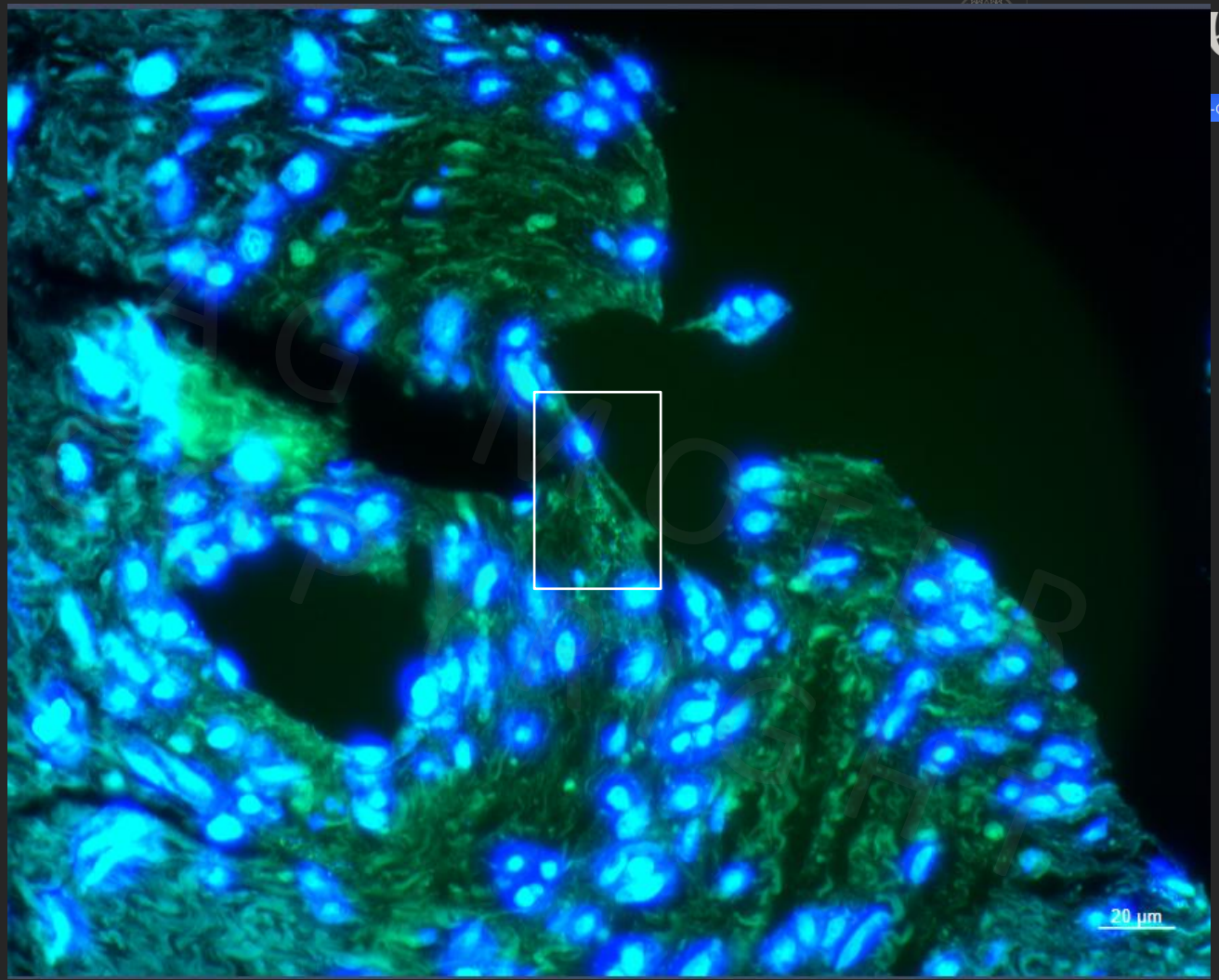

Universitätsklinikum Leipzig
Medizin ist unsere Berufung.

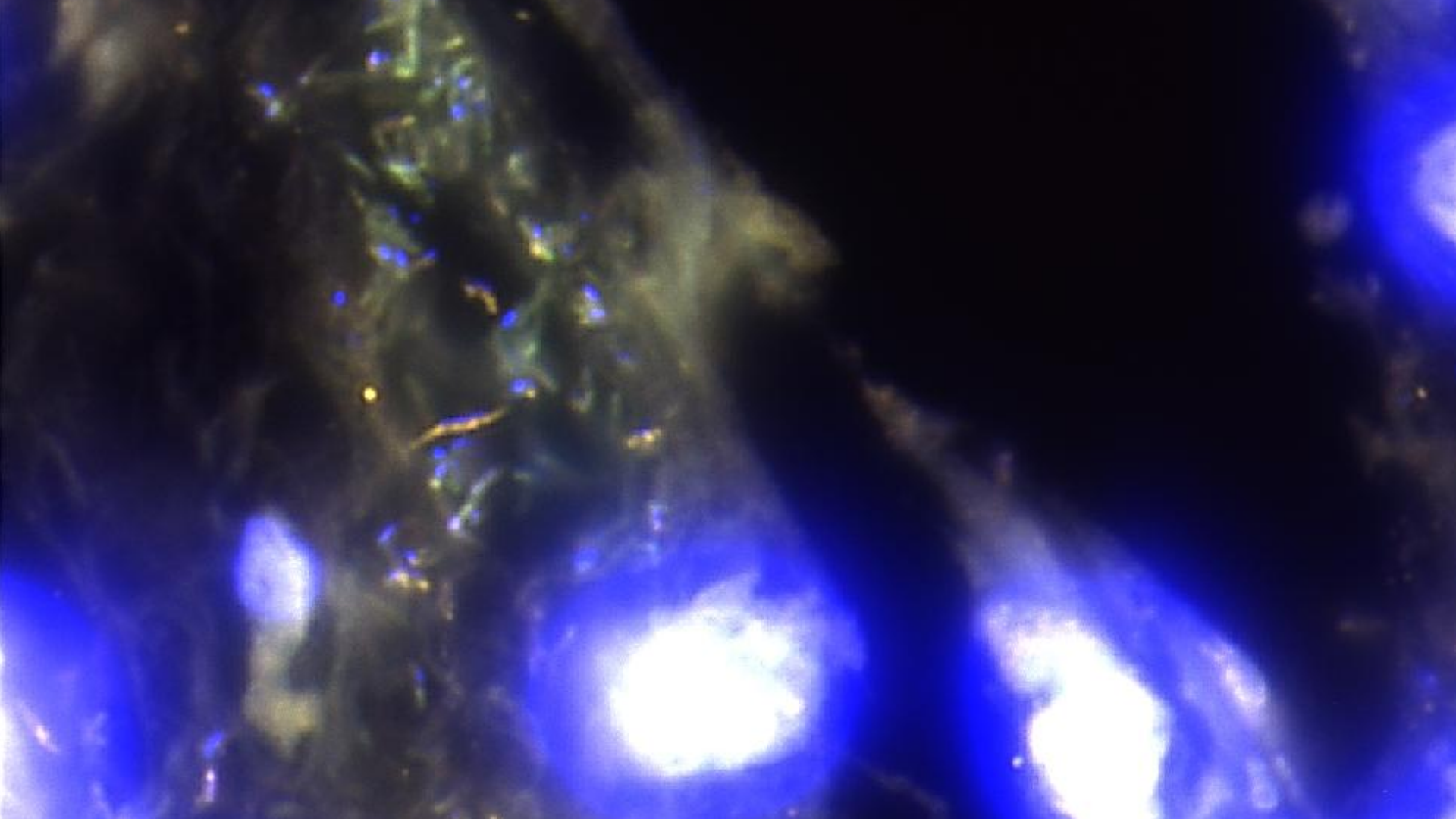

BioIntegral Surgical

ABOUT US EEA/UK NEWS INTERNATIONAL NEWS PRODUCT FEEDBACK

BIOCONDUIT™



Case 1

UNIVERSITÄT LEIPZIG
Medizinische Fakultät
Universitätsklinikum Leipzig
Medizin ist unsere Berufung.





20201251_Kinyon

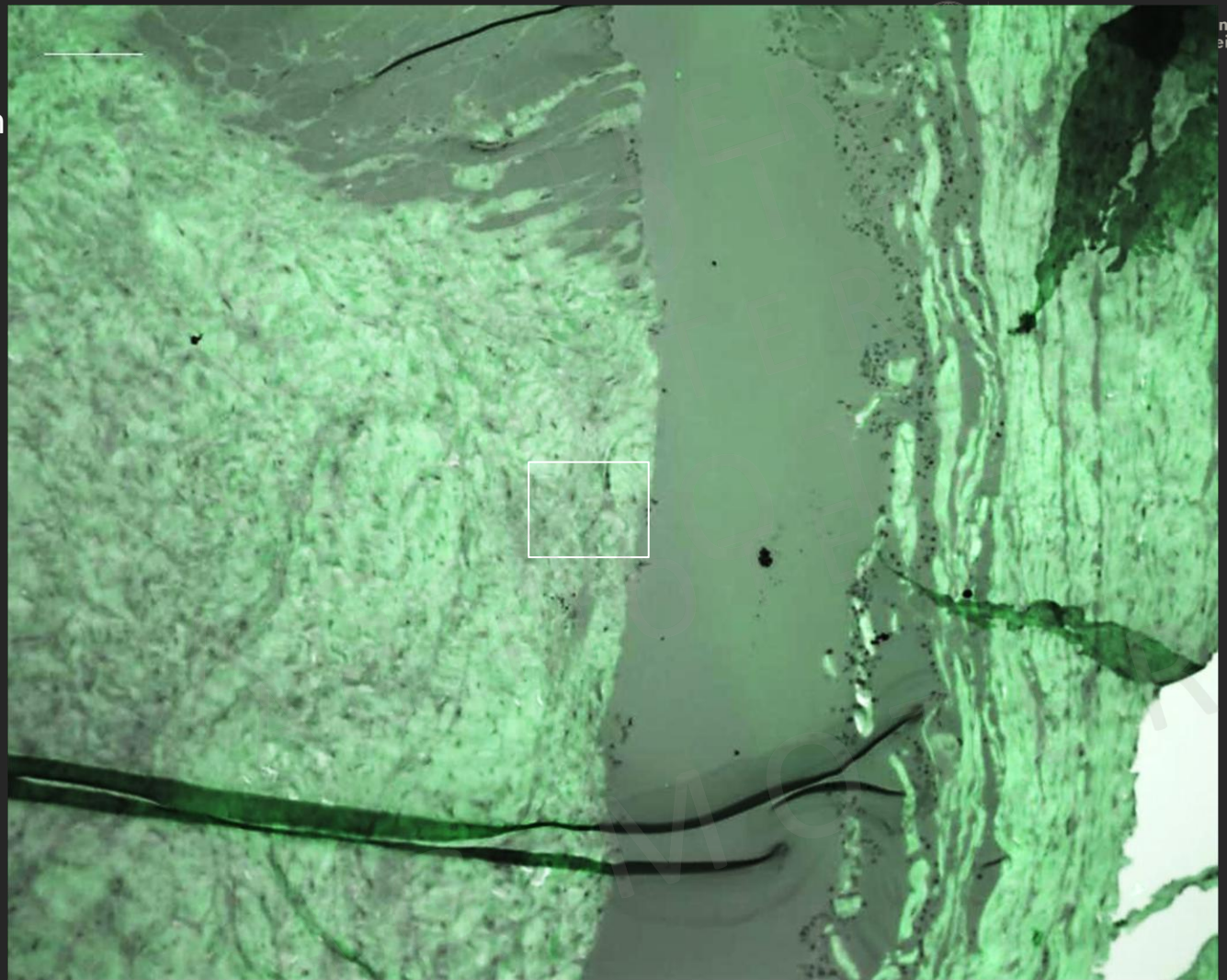

niversitätsklinikum
eipzig
Medizin ist unsere Berufung.

100 µm

Case 1 - Kinyoun



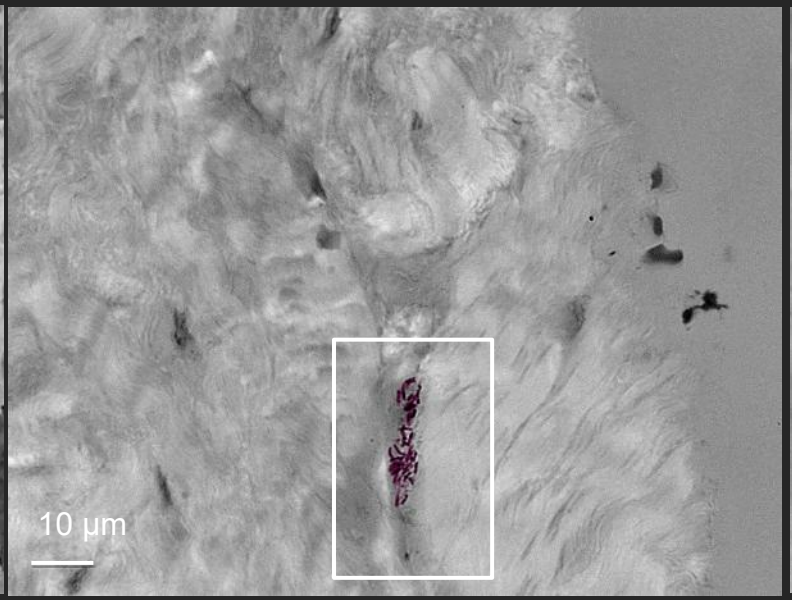

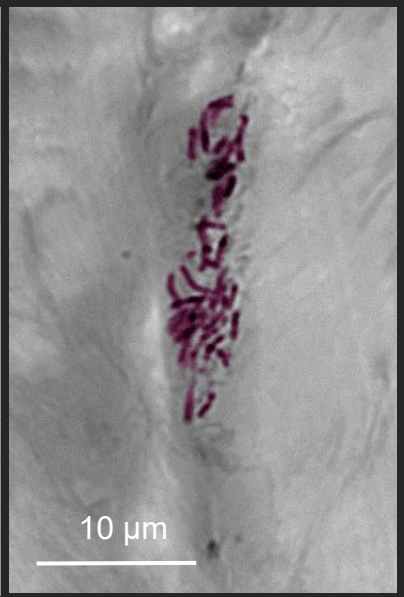

20201251_Kinyon _ I.Friesen

Case 1 - FISH

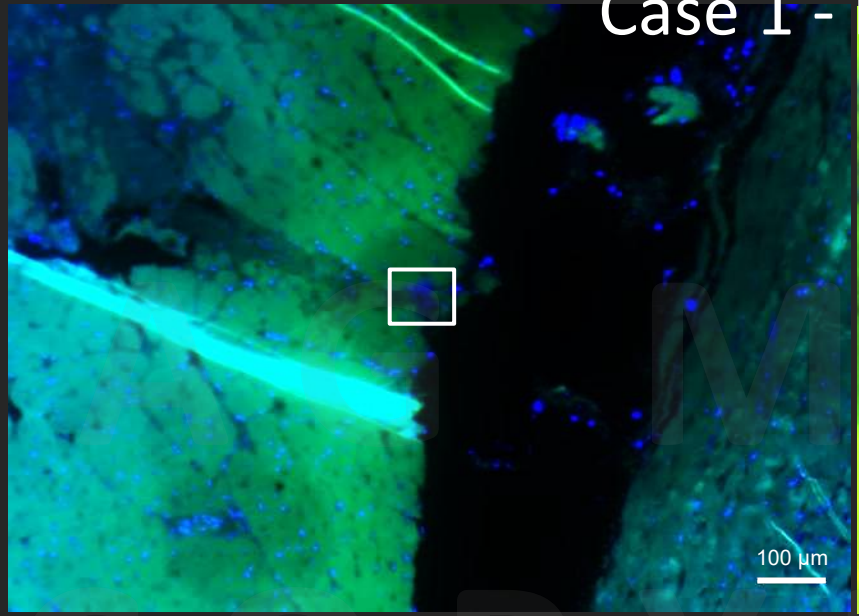

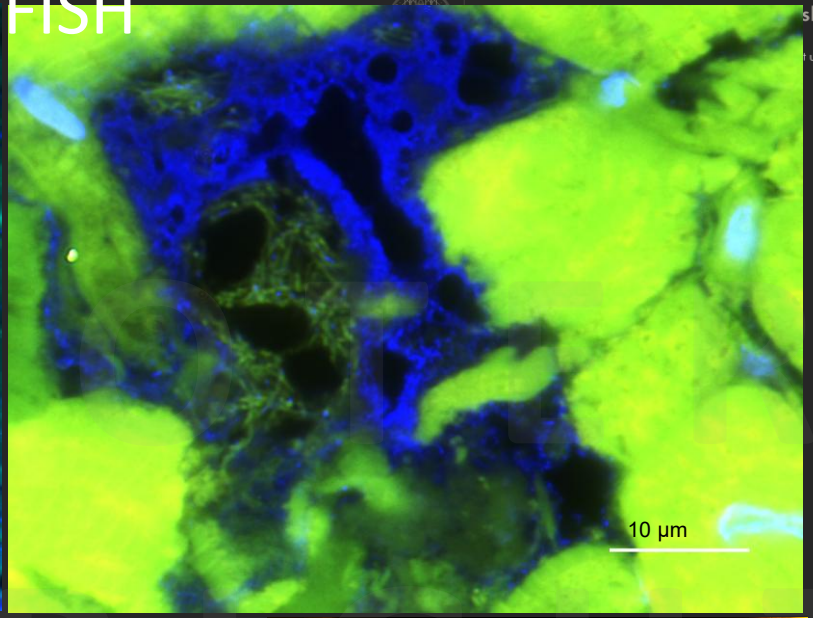



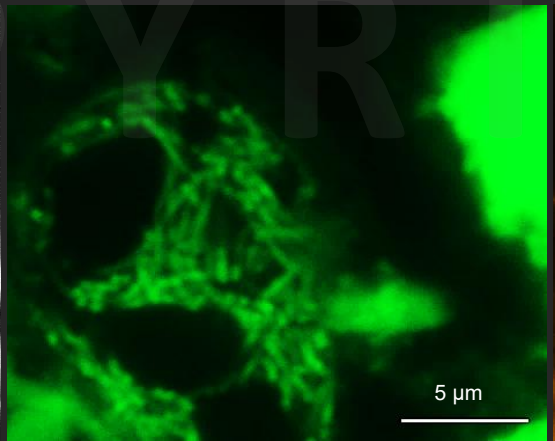

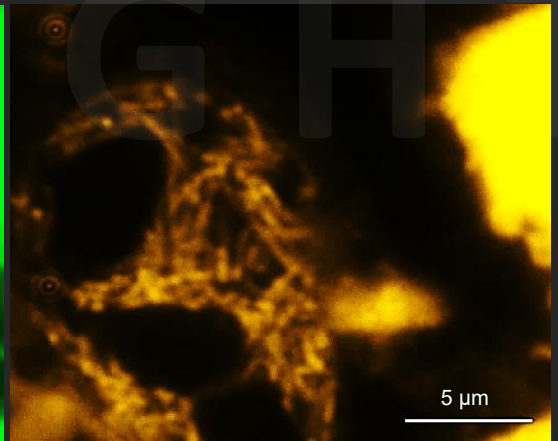

Case 3 - FISH

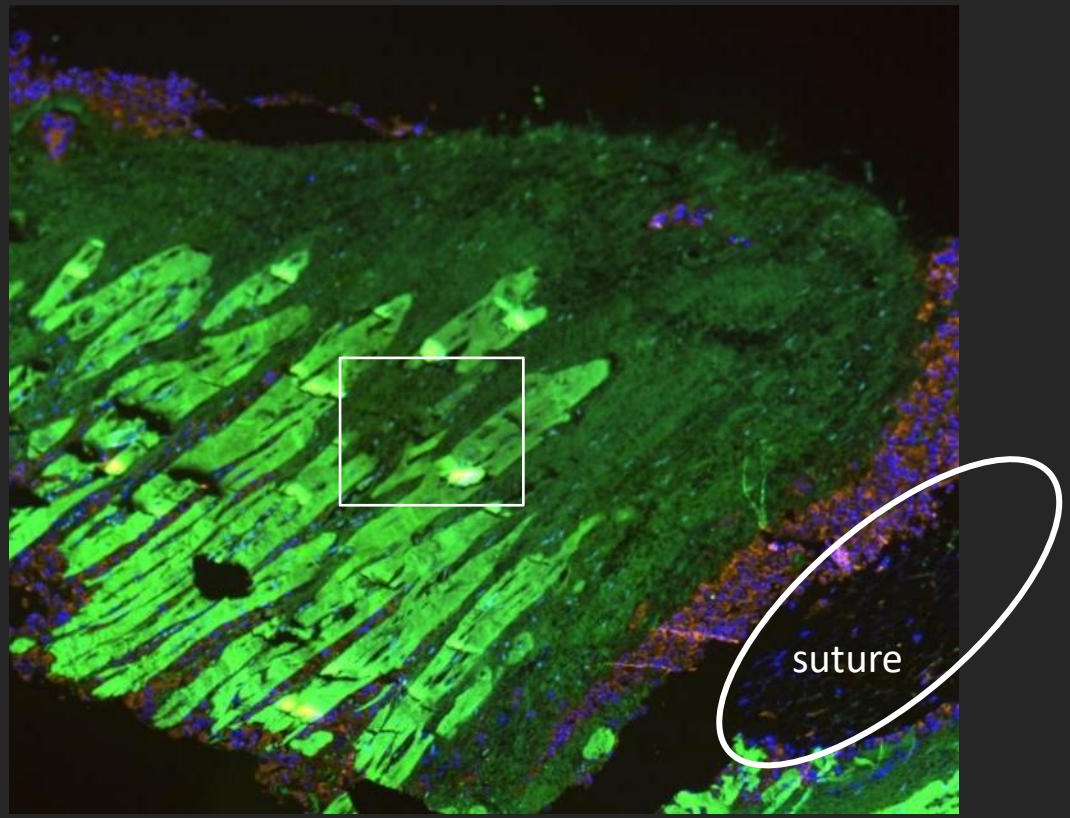

Case 3 – FISH + HE



Universitätsklinikum Leipzig
Medizin ist unsere Berufung.

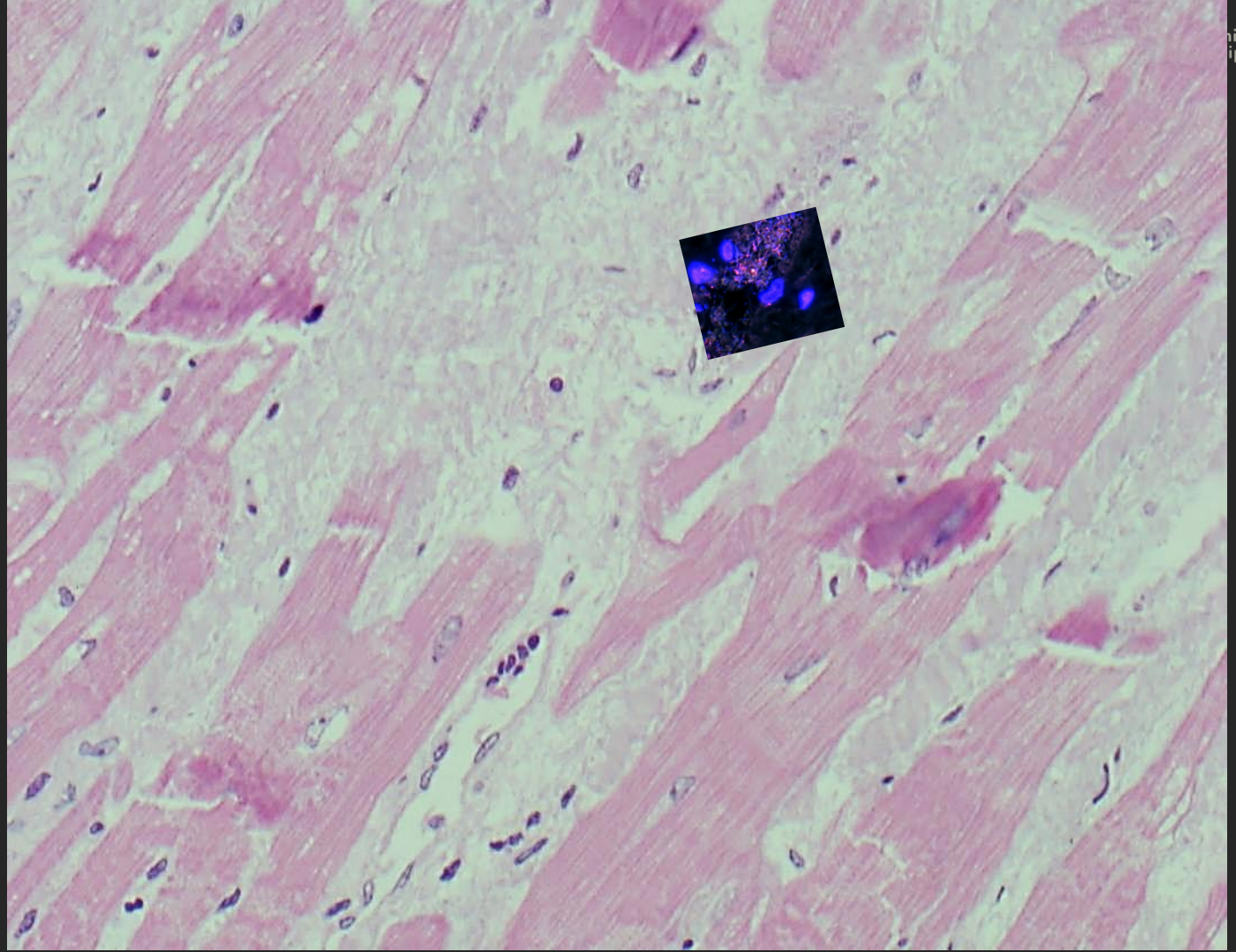

niversitätsklinikum
ipzig
Medizin ist unsere Berufung.

Case 3 - FISH

20220156_2_9_FISH220225_EUB-PNA-FITC_NTM-Cy3_DAPI_100x

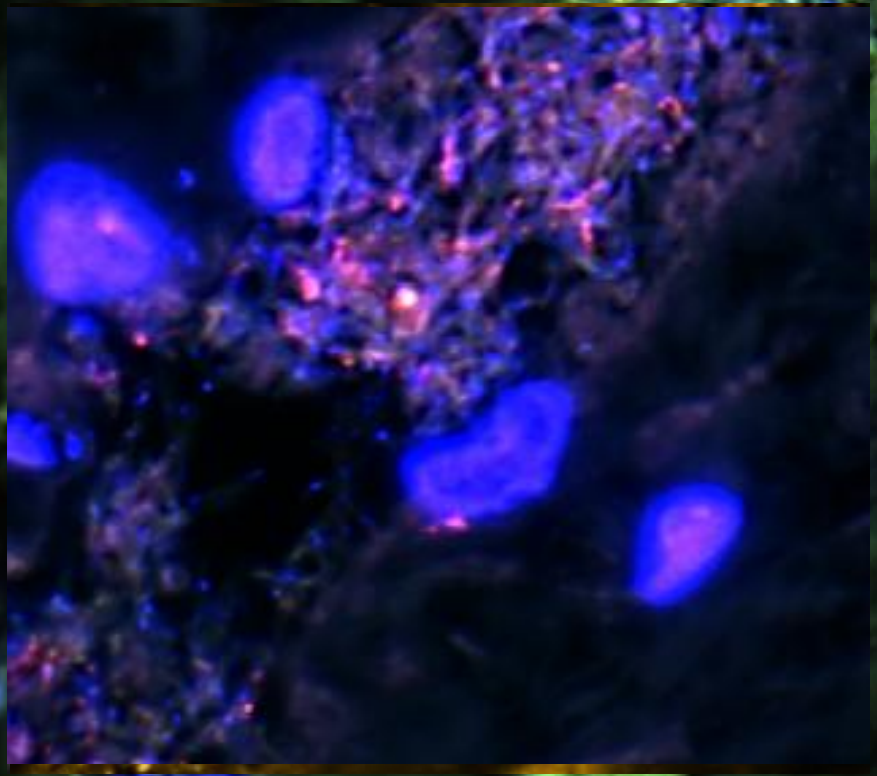

Loddenkemper

Case 1 - Histology

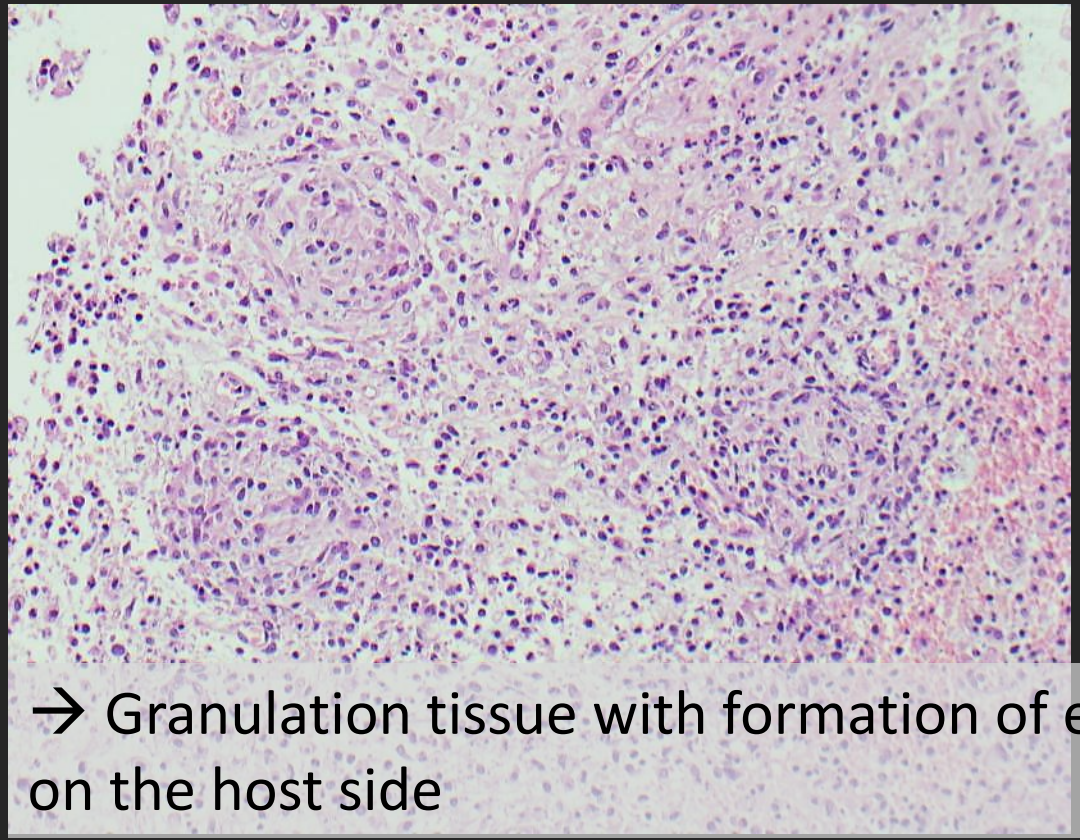

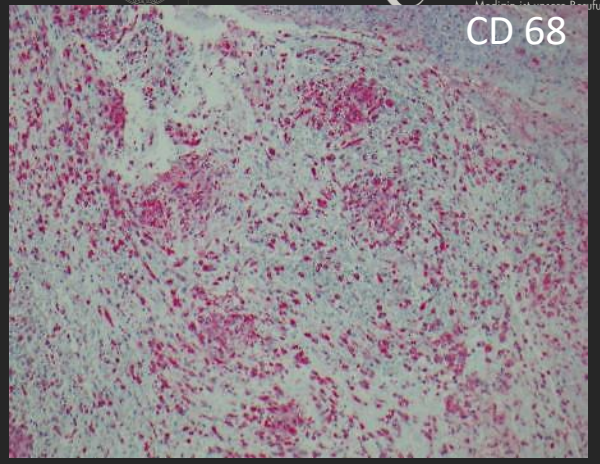

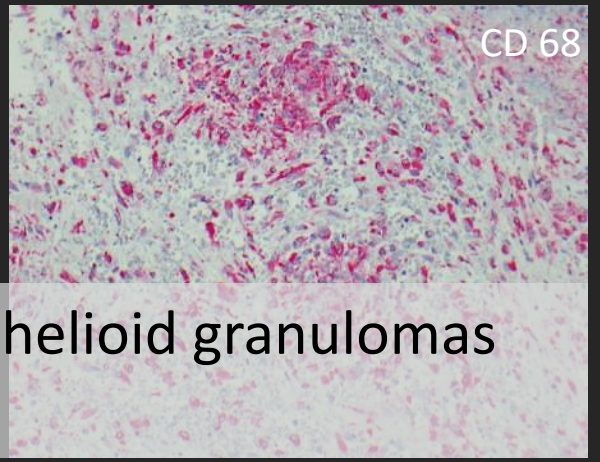

→ Granulation tissue with formation of epithelioid granulomas on the host side

HE-stain

CD68 Immunostain

Case 1 - Auramin

UNIVERSITÄT LEIPZIG
Medizinische Fakultät

Universitätsklinikum Leipzig
Medizin ist unsere Berufung.

Auramin Friesen
Image FISH Team



Timeline

Initial 3 cases

12/2020 – 02/2022

M. chelonae initially found by routine FISHseq in explanted prosthetic heart valves from three patients

→ all prostheses from the same manufacturer

Notification

02/2022

to the German competent authority

Unused Prostheses

Investigation of 12 unused prostheses from the same manufacturer, all positive for *M. chelonae*

Alert in EU

Alert raised by competent authorities in the EU

Retrospective evaluation of FISHseq results

from 1,237 cardiovascular samples (2015-2022)

Additional 3 cases

M. chelonae found in explanted prosthetic heart valves from three additional patients in Germany plus one additional case from France

Additional 3 cases

M. chelonae found in explanted prosthetic heart valves from three additional patients in Germany

12/2020 - 02/2022 | 02/2022 – 12/2022 | 01/2023 – 06/2023

To the paper:

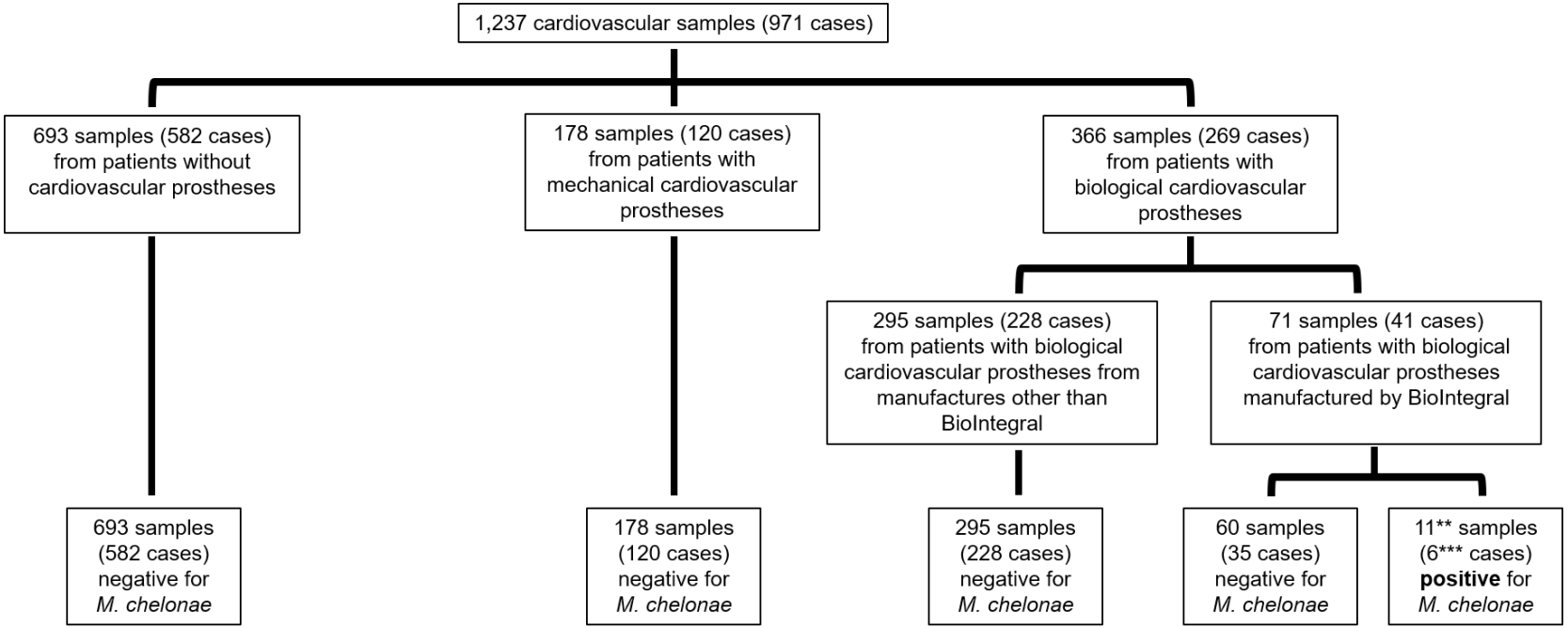

** Including two samples positive for both *M. chelonae* & *S. aureus*
*** Including one case positive for both *M. chelonae* & *S. aureus*



Forschungszentrum Borstel
Leibniz Lungenzentrum

Leibniz Gemeinschaft

German National Reference Center for Mycobacteria

Parkallee 18
D-23845 Borstel

Tel: +49.4537.188 2110
Fax: +49.4537.188 3110

nrz@fz-borstel.de
www.fz-borstel.de

FZB • Parkallee 1-40 • D-23845 Borstel

Forschungszentrum Borstel - Leibniz Lungenzentrum

Protocol for optimized detection of *M. chelonae* in bioprosthetic cardiac implants

STEP 1: Implants and the tissues around the implants that need to be removed shall be transferred into sterile containers in the operating theatre and transferred to the microbiology laboratory as soon as possible.

STEP 2: New valves shall be transported unopened in the sealed original container.

STEP 3: Operators performing the below analyses must be qualified laboratory staff trained to work with mycobacteria. Operators must strictly adhere to all standard laboratory hygiene and biosafety procedures at all times.

STEP 4: Upon arrival at the laboratory, take photos of the transport container, the product lot and serial numbers (for new valves) and the seal of the transport

Sample workup protocol in the supplemental material

To the paper:

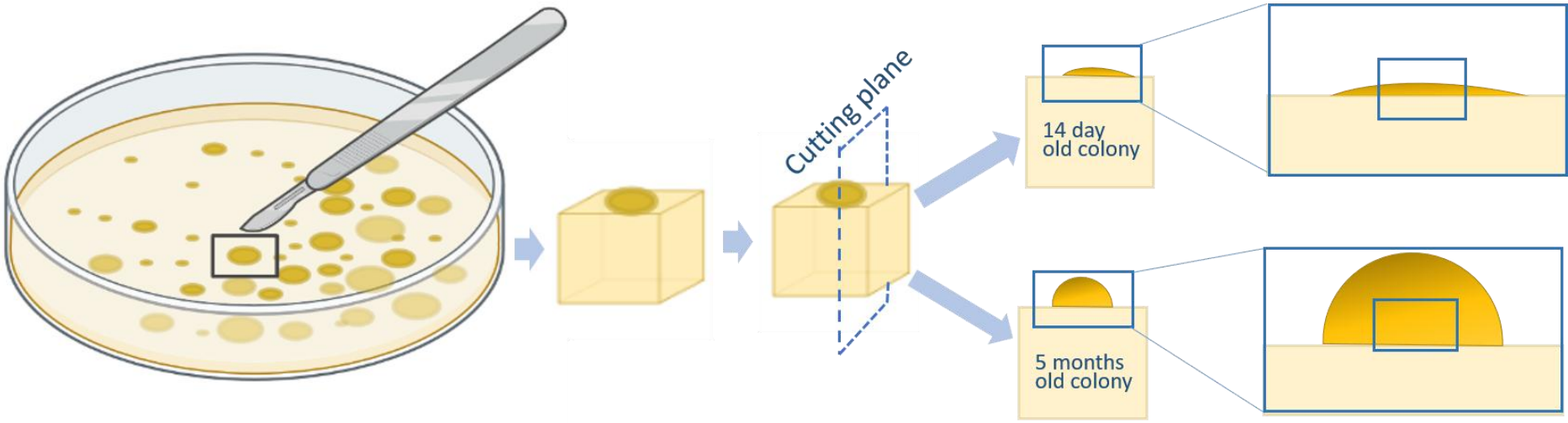
Cutting plane
14 day
old colony
5 months
old colony

PNA-FISH controls

UNIVERSITÄT LEIPZIG

Universitätsklinikum Leipzig
Medizin ist unsere Berufung.

M. chelonae
colony
2 weeks old

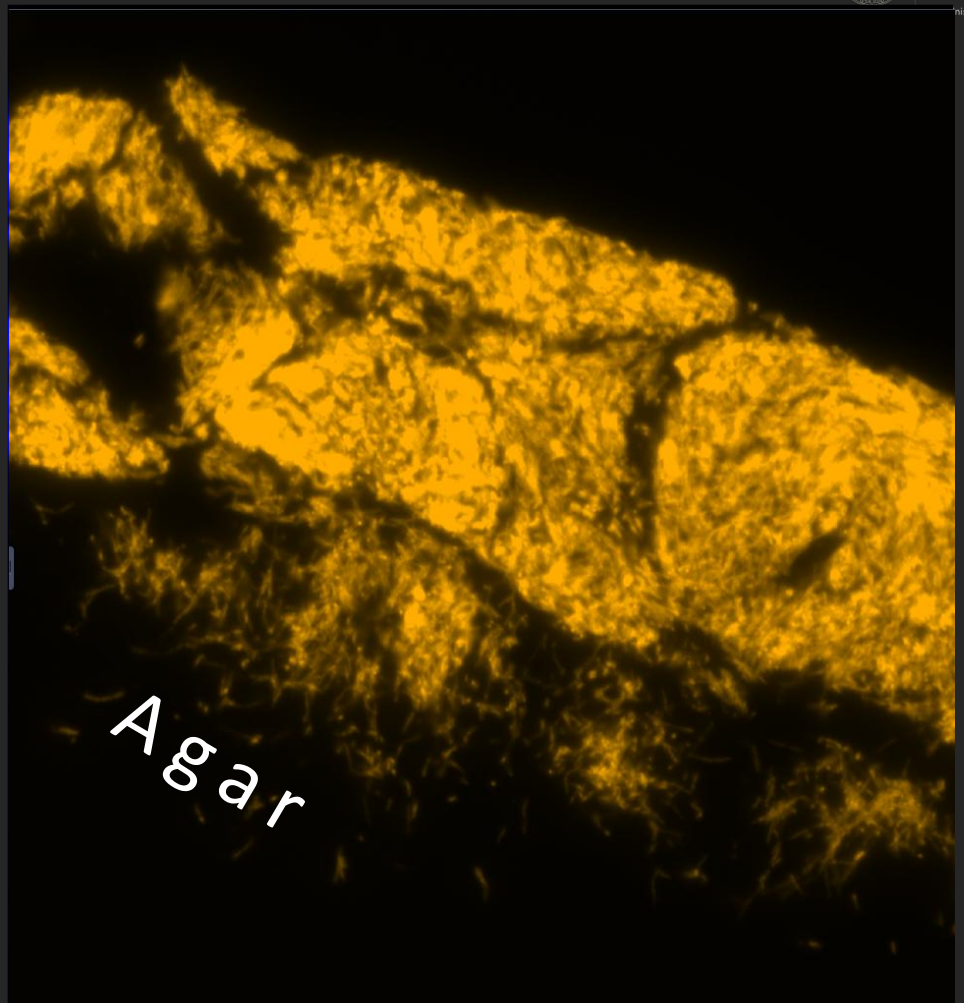

M. chelonae
colony
5 months old

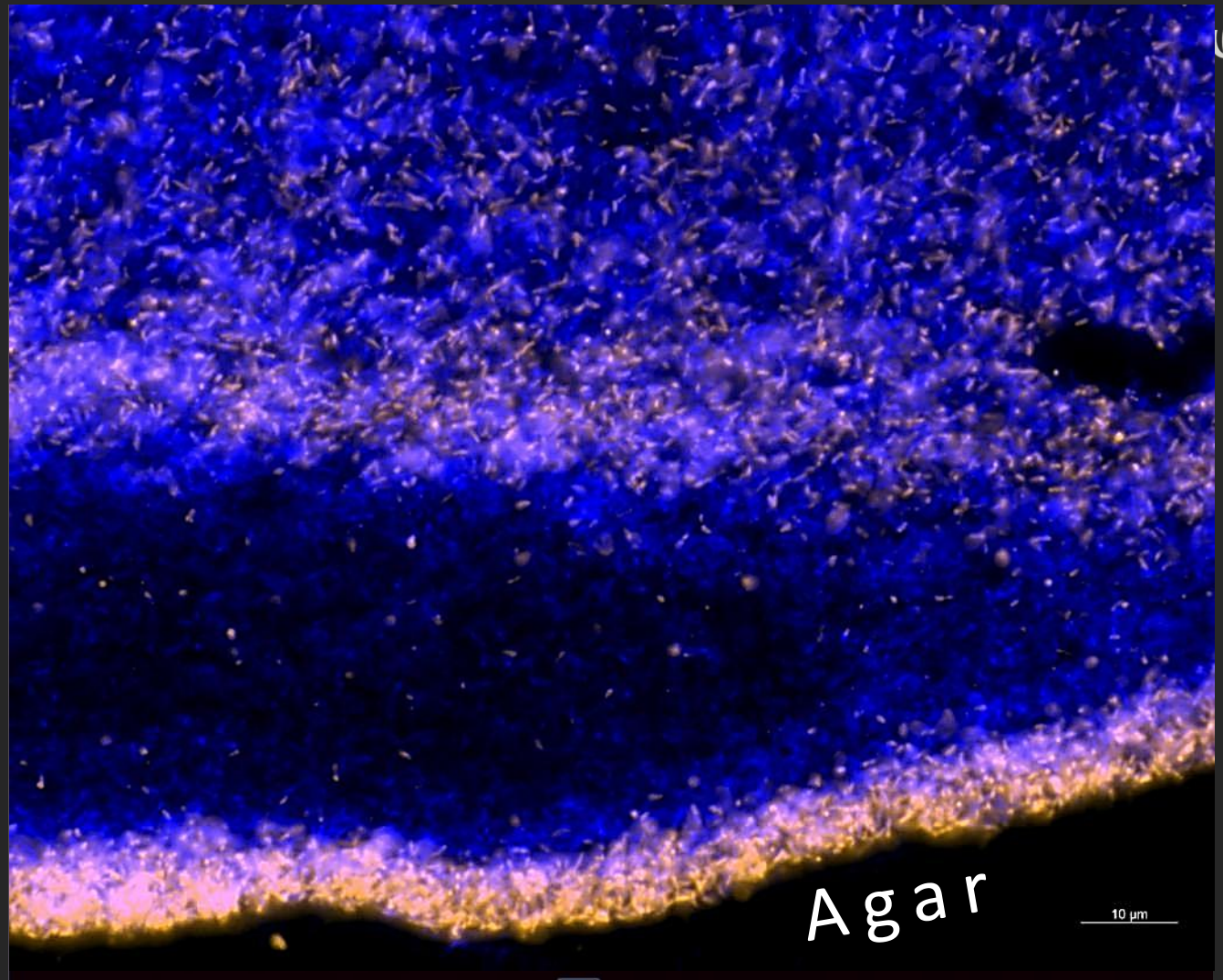

Mix11_20220803_M. chelonae_FISH220824_PNA_BacUni-FITC_NTM-Cy3_STREP1-Cy5_DAPI_HP60_100x_60°C_DAPI s_w

Universitätsklinikum Leipzig
Medizin ist unsere Berufung.

Zusammenfassung

- 17 Patienten mit *M. chelonae*, selbe Herstellerfirma (BioIntegral)
- Nicht beschränkt auf Berlin
- Nicht beschränkt auf ein Labor
- Bisher nur BioIntegral Prothesen betroffen
- 12 original-verpackte BioIntegral Klappen + 3 Patches positiv

- Bisher kein Wachstum in Kultur
- Aber: morphologisch intakte, DNA und RNA haltige Mykobakterien im Gewebe auf der Wirtsseite

Bottom line

- PatientInnen haben keine klassischen IE-Symptome!
- Awareness!
- Überwachung der PatientInnen (PET-CT?)
- Klinische Optionen
  - explantieren?
  - Anti-mykobakterielle Therapie mit Nebenwirkungen?
  - ‚wait and see' ?

→ Internationales IE-Board

- Register ‚MYBACH', Frieder Pfäfflin

https://drks.de/search/de/trial/DRKS00034062