

## Kasuistik 10-21

43-jähriger Mann

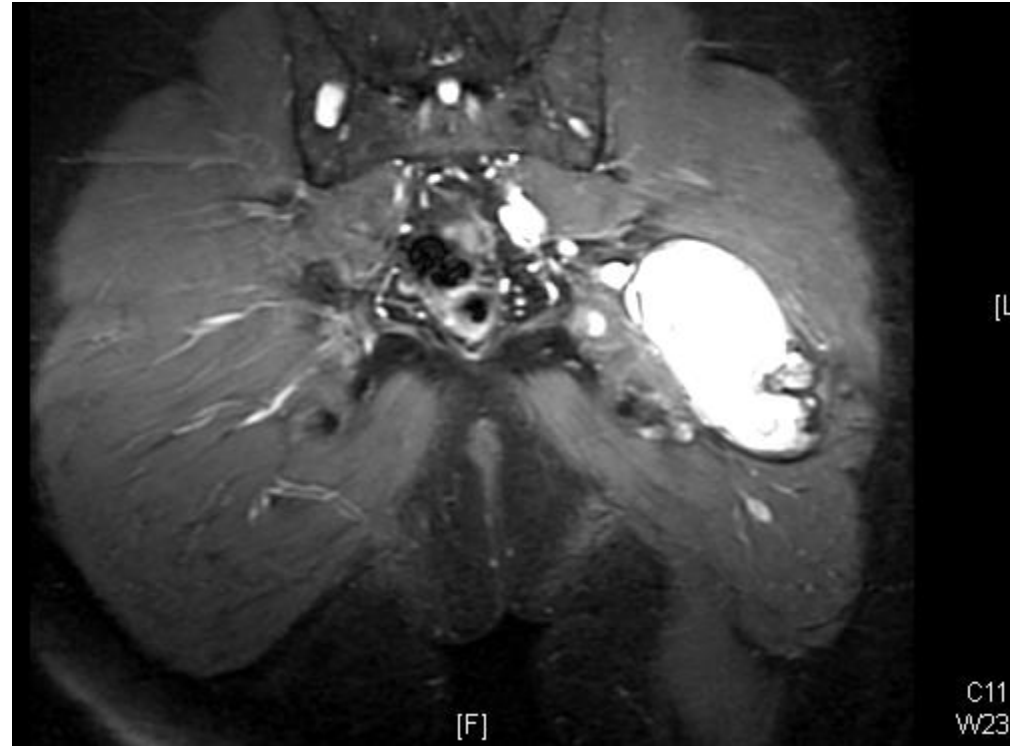
Raumforderung gluteal links

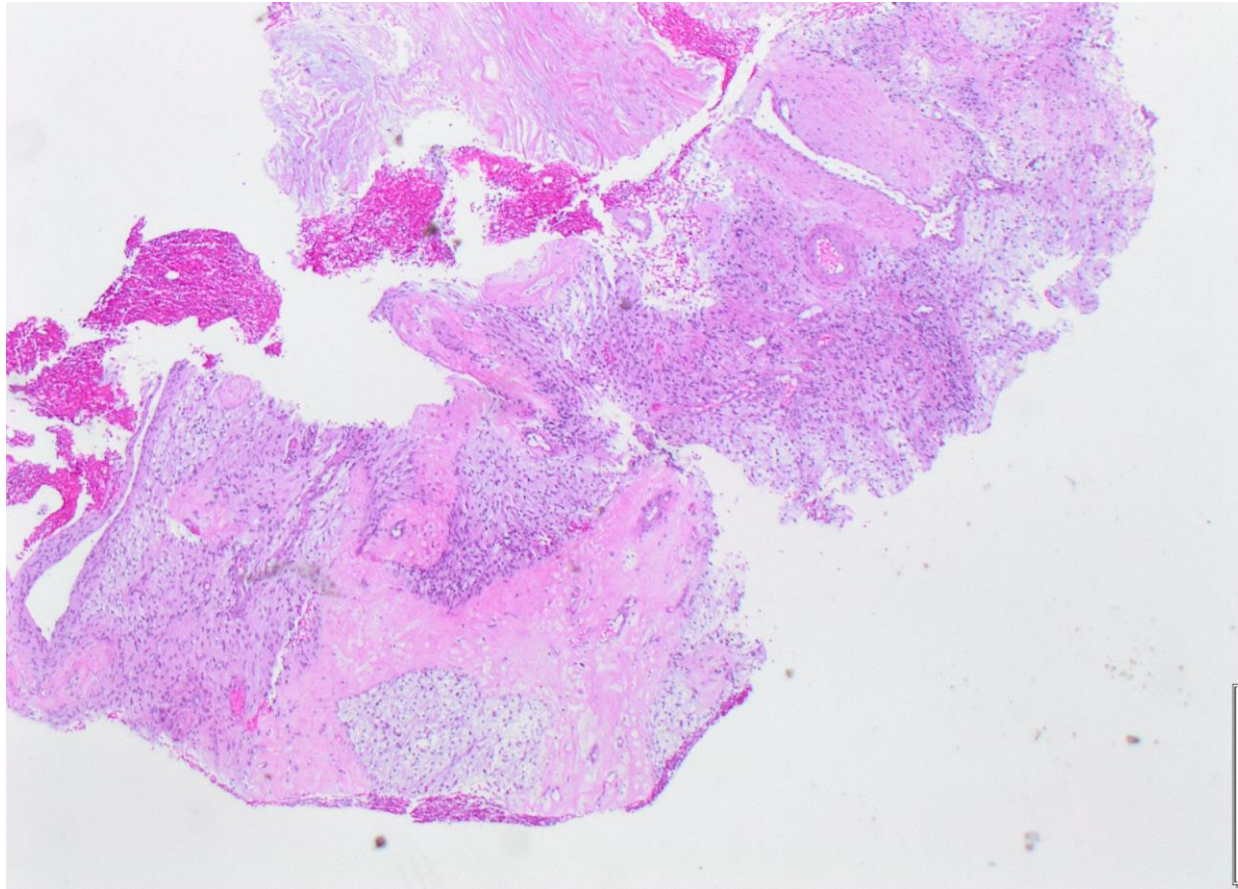
V.a. Sarkom

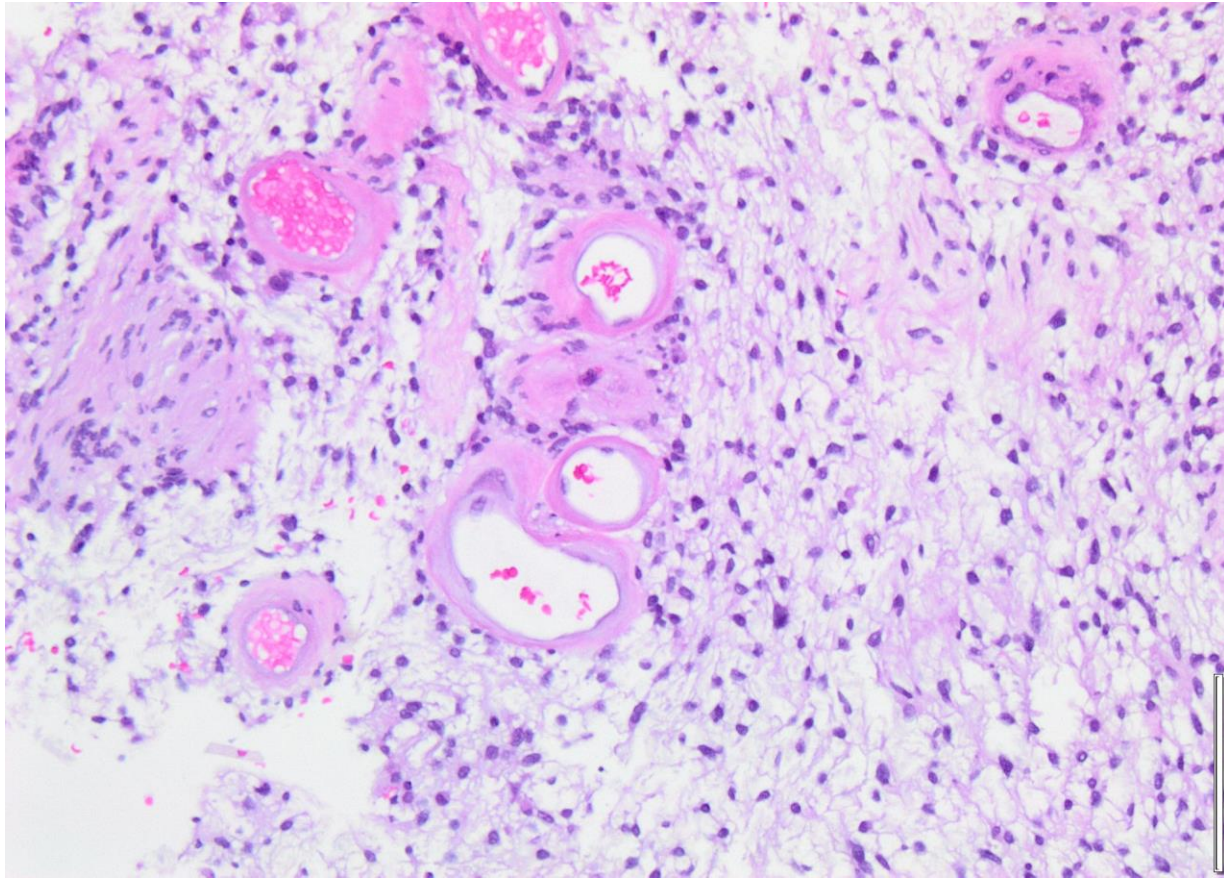
Befund

6,5 cm scharf demarkierte

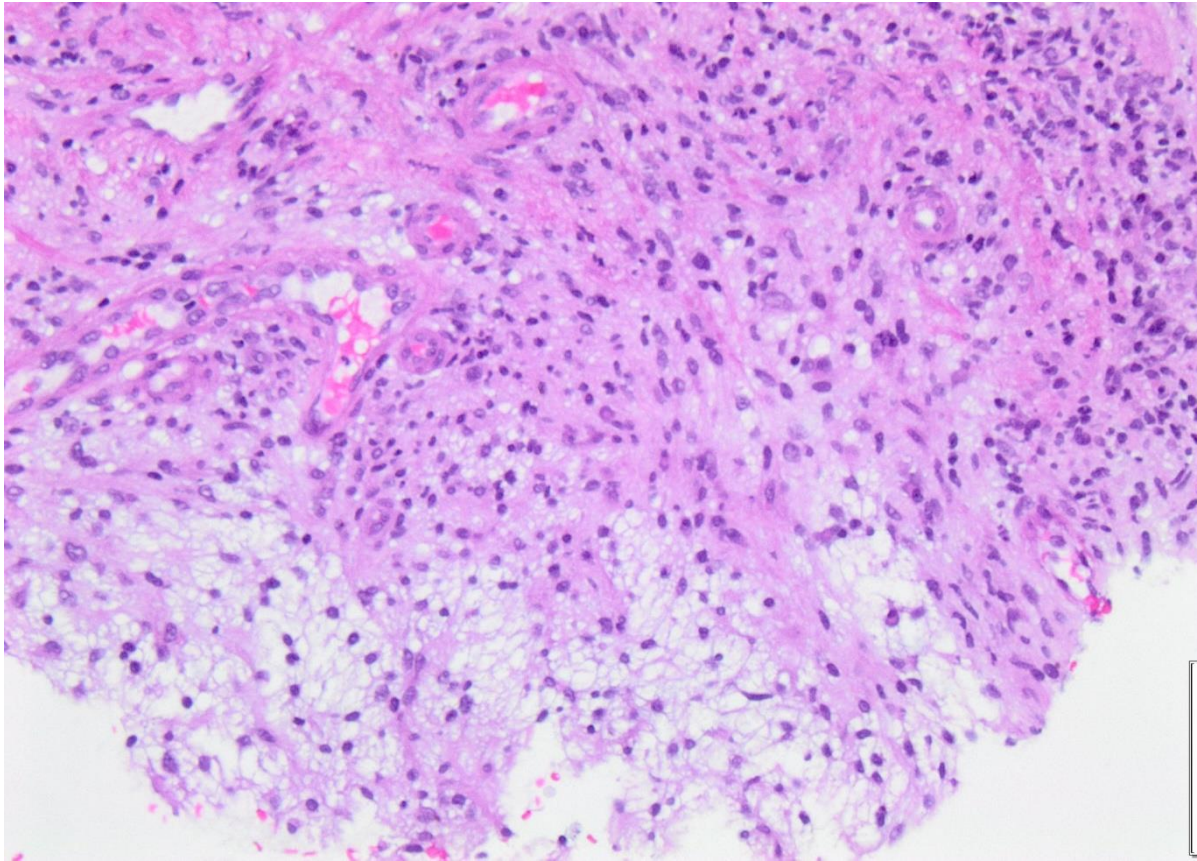
Läsion

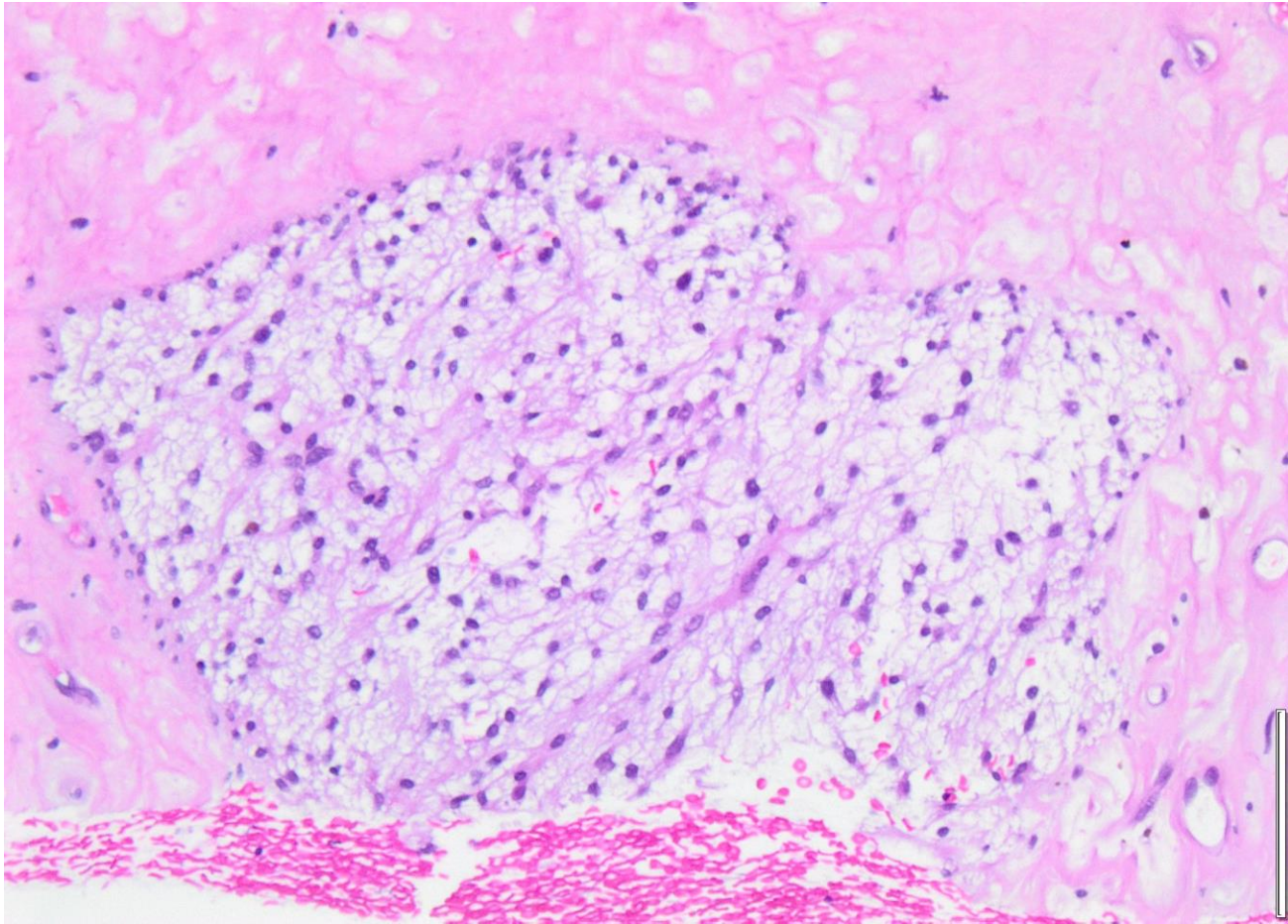




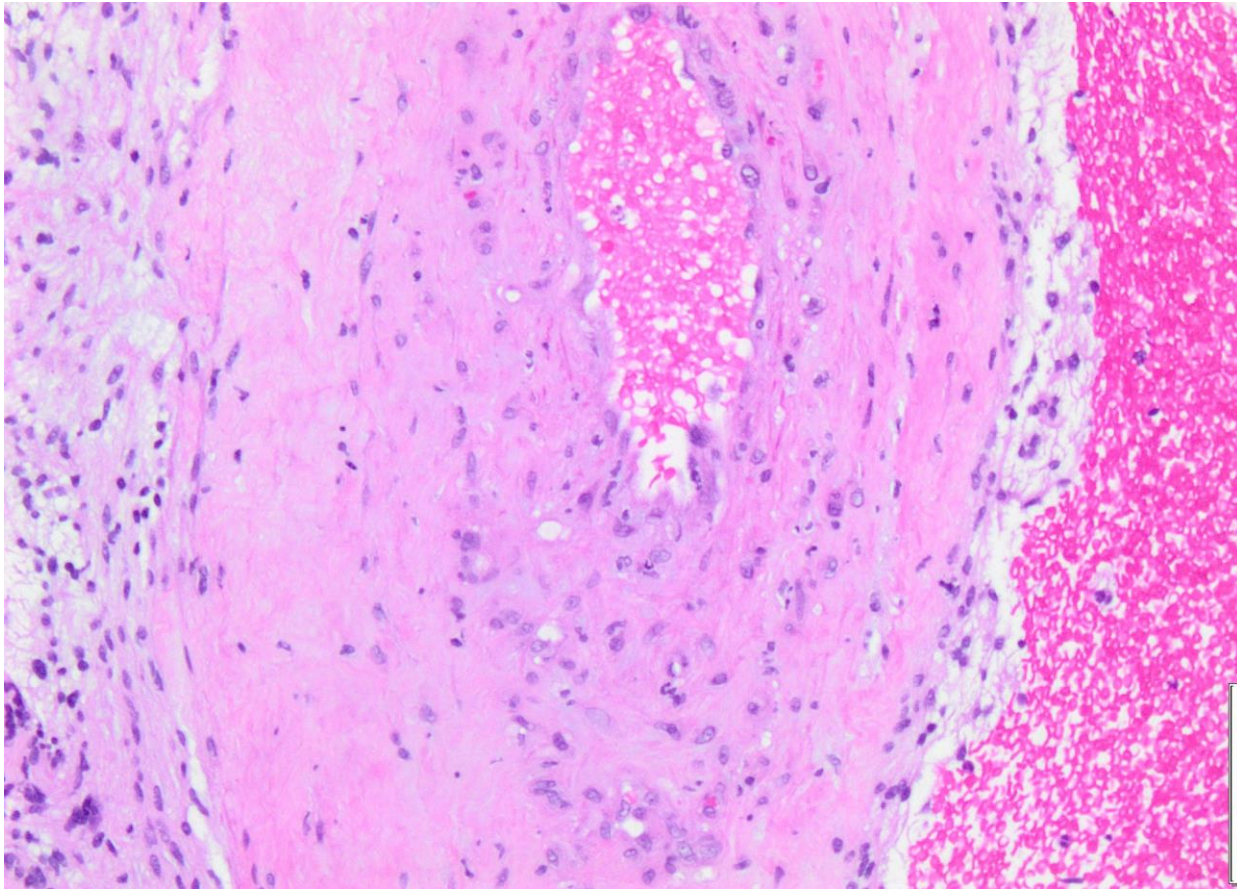












## Kasuistik 10-21

Welche Zusatzuntersuchungen beauftragen Sie?

Welche Diagnose stellen Sie?