

Kasuistik 13-21

71-jährige Frau

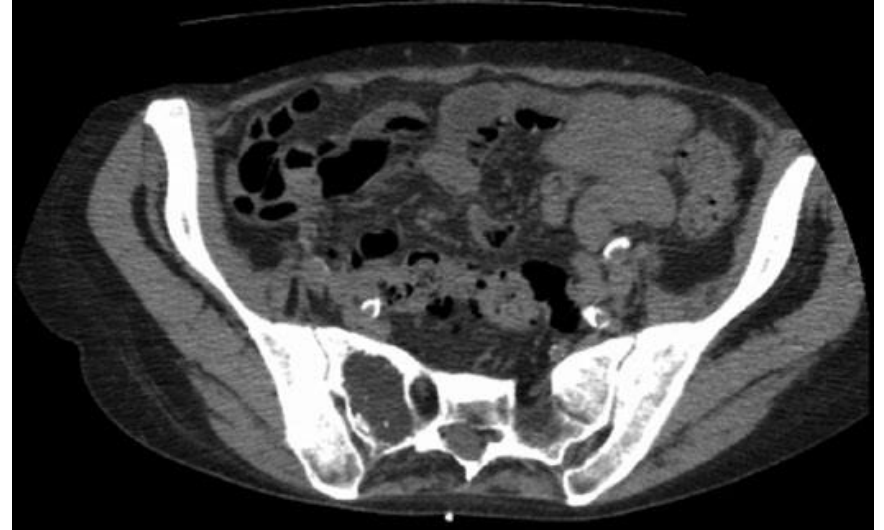V.a. Tumor rechtsseitiges

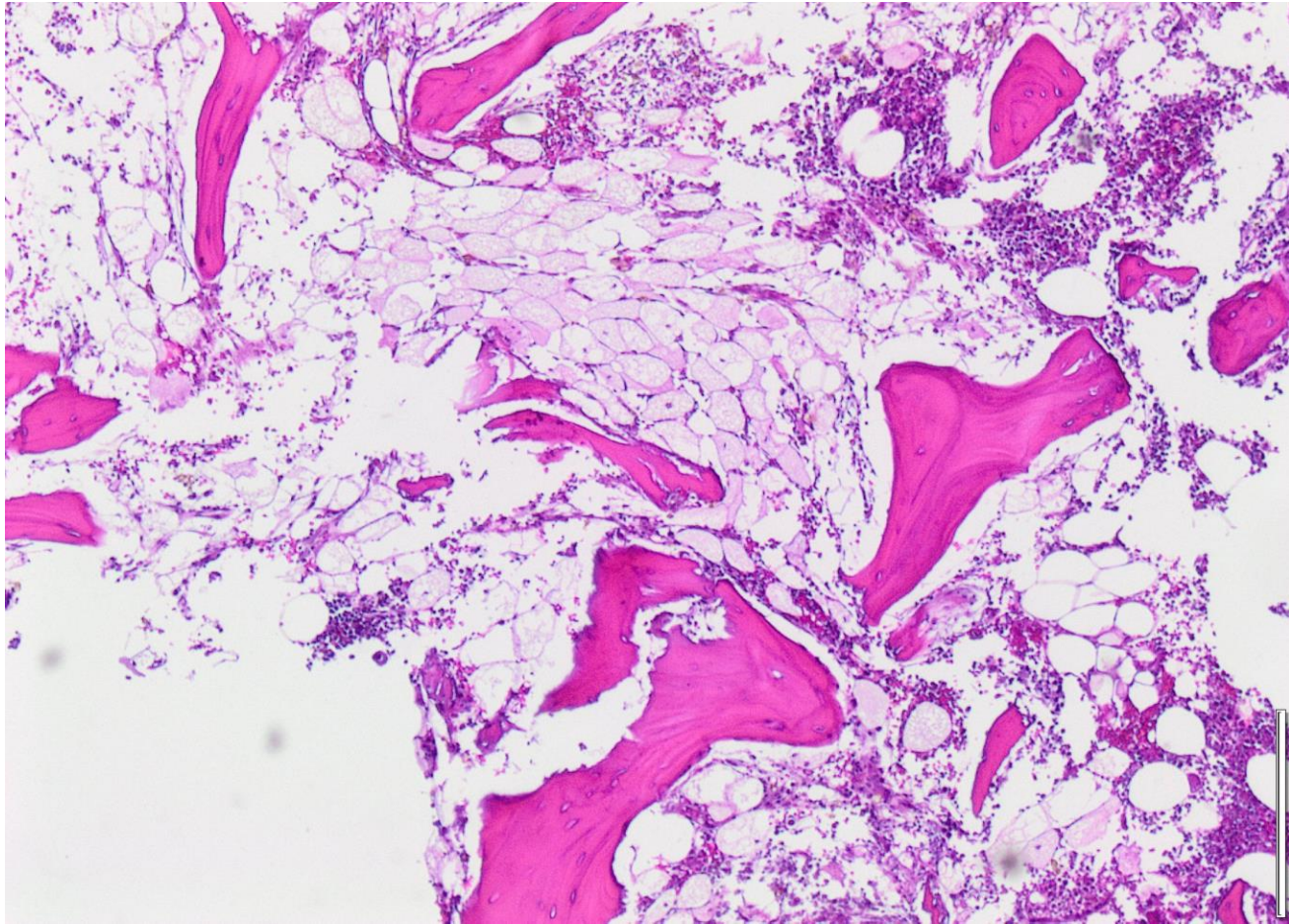
Os sacrum

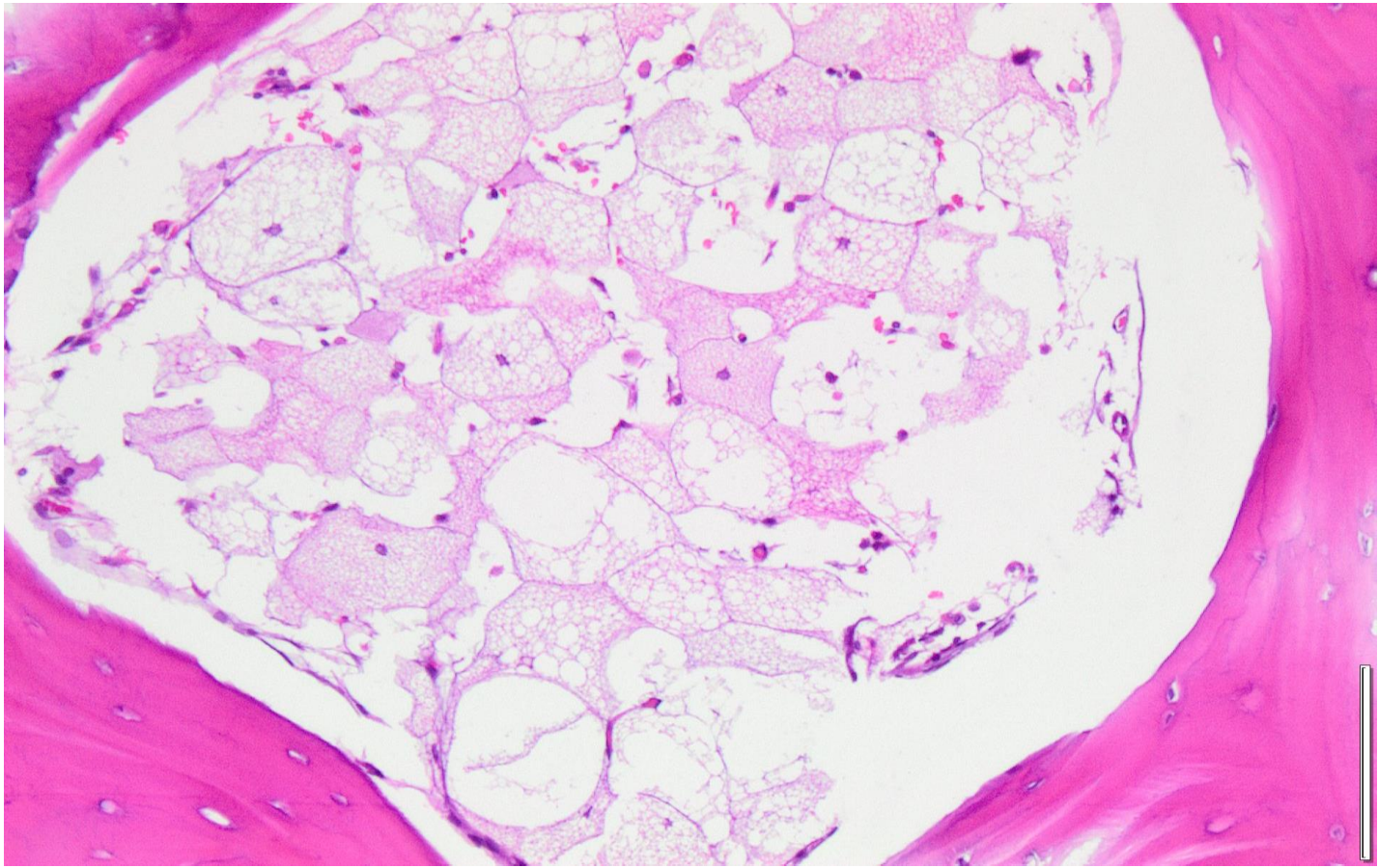
Befund

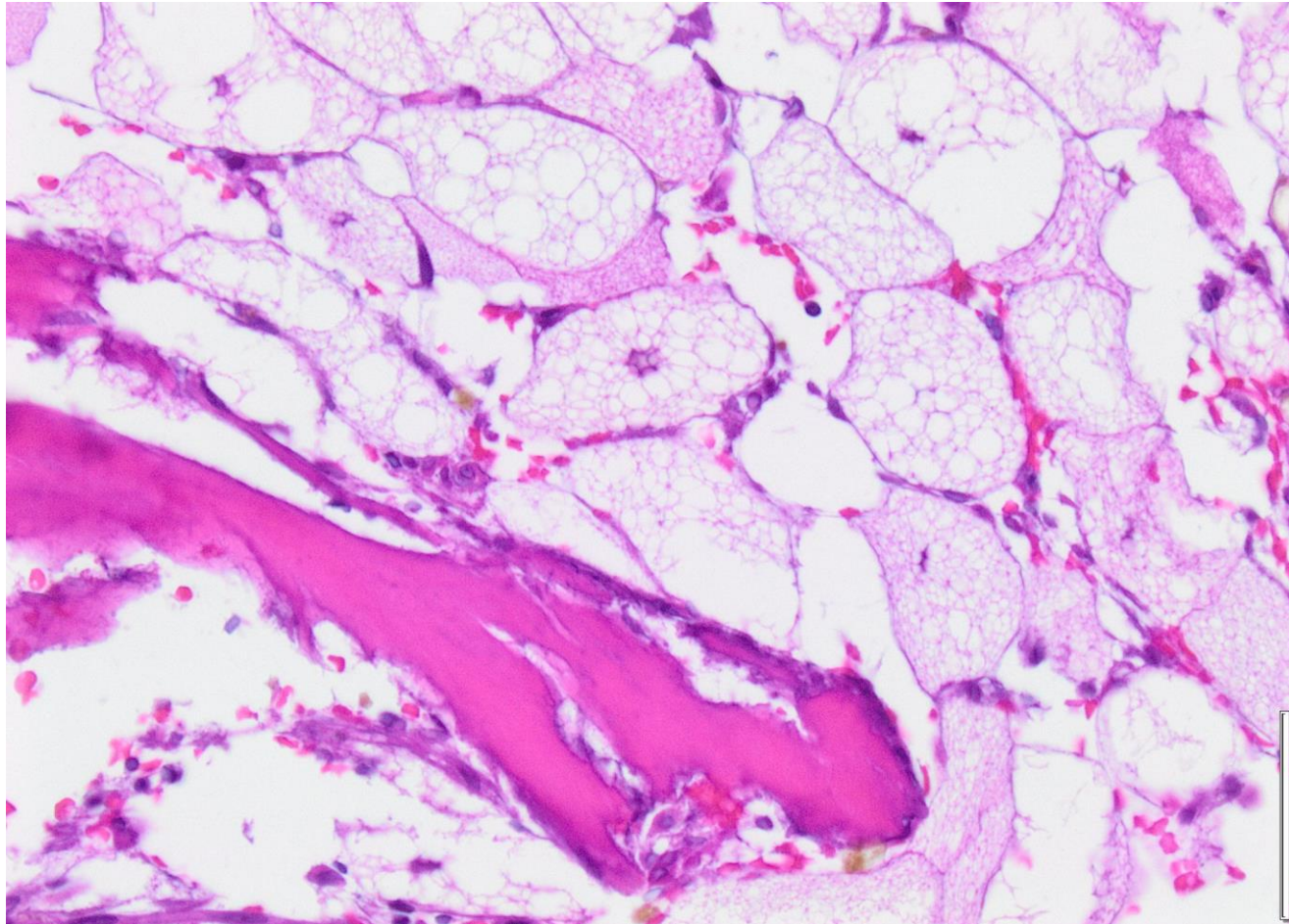
5 cm unscharf demarkierte

Läsion intramedullär

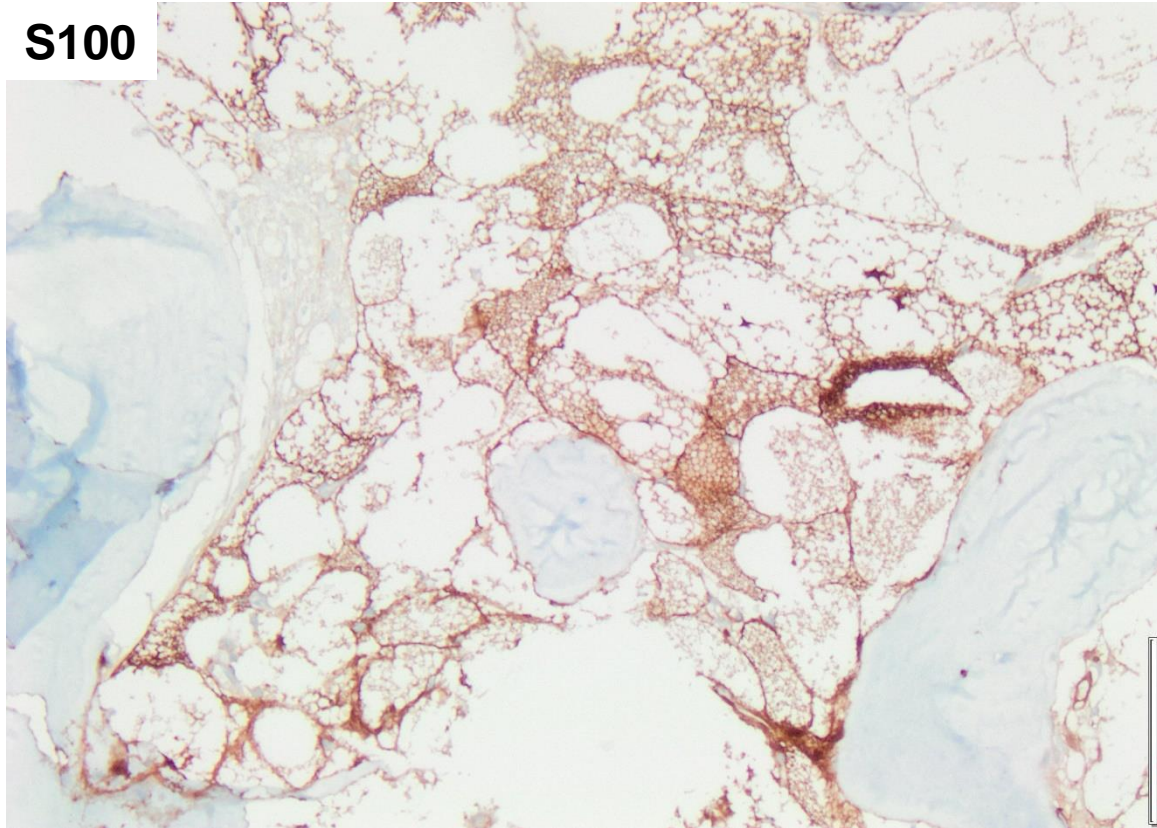








S100



Kasuistik 13-21

IHC

Positiv: S100

Kasuistik 13-21

Welche Zusatzuntersuchungen beauftragen Sie?

Welche Diagnose stellen Sie?