

Kasuistik 15-21

58-jährige Frau

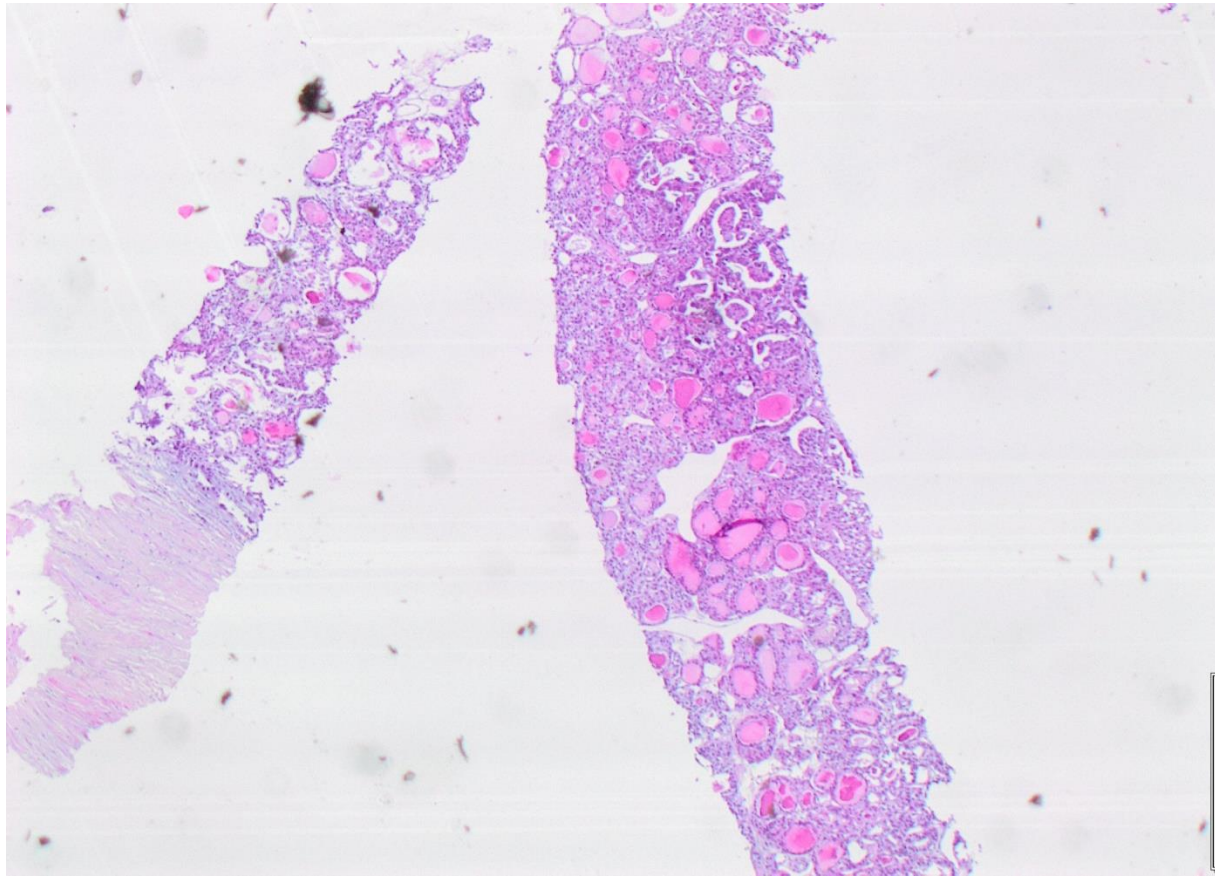
kalter Knoten in der

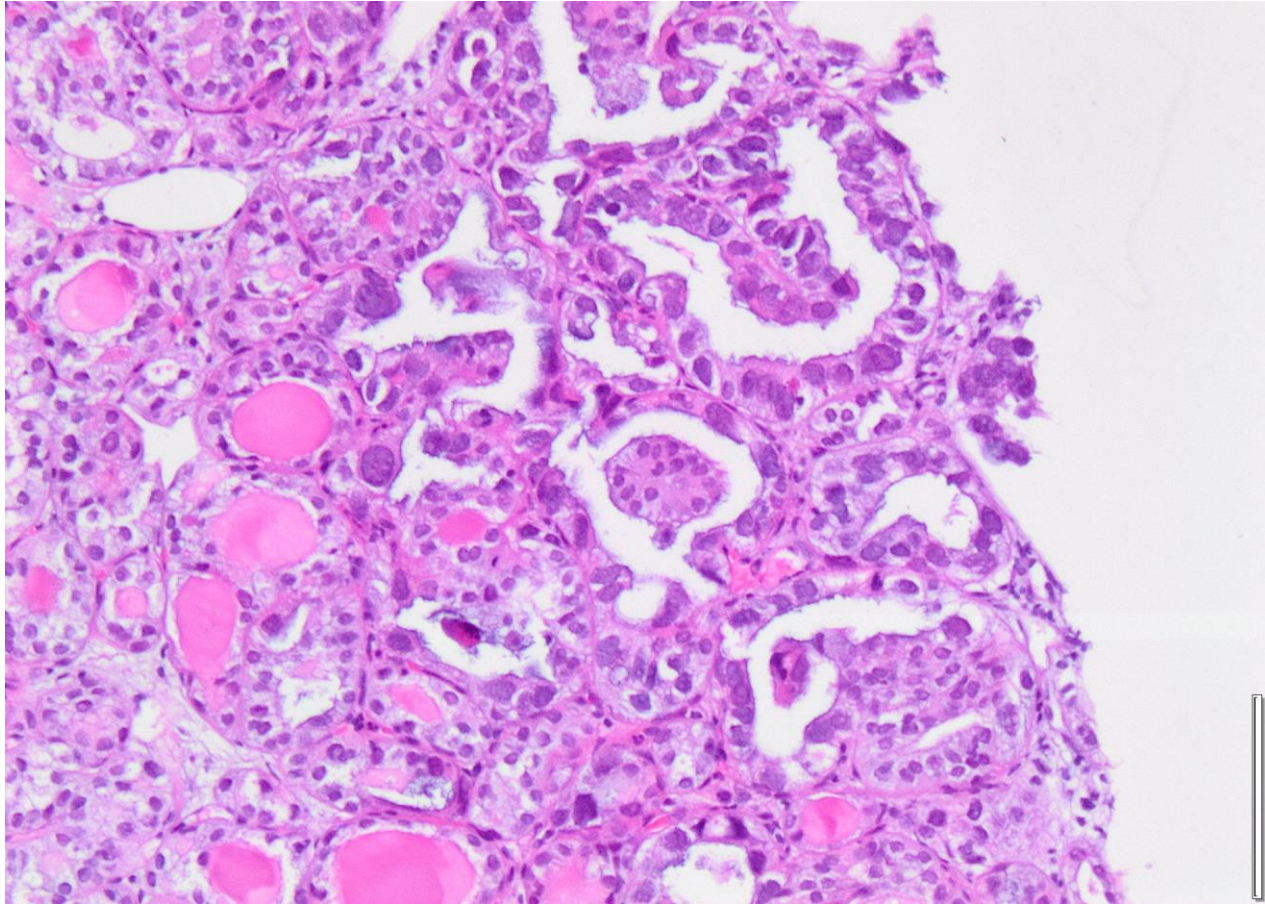
Schilddrüse

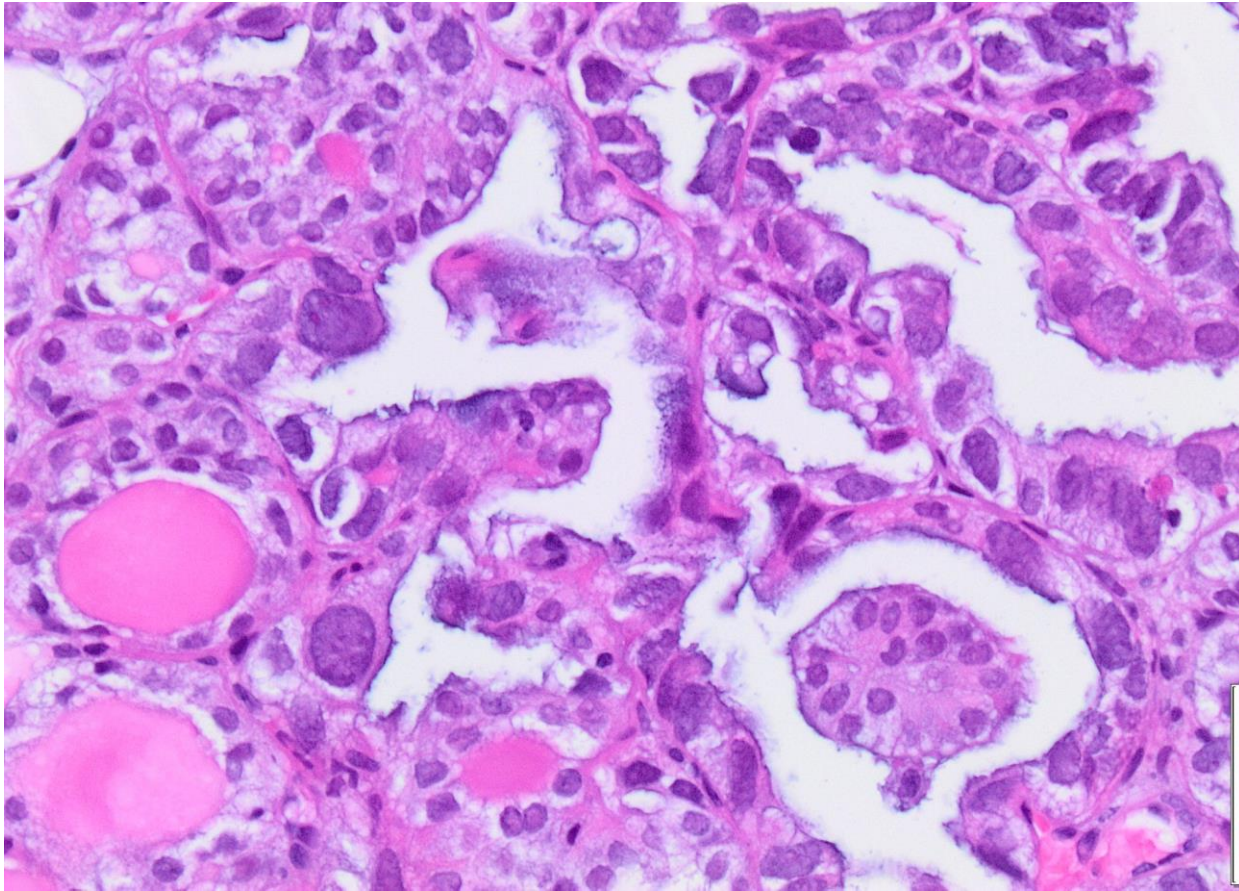
V.a. multiple

ossäre & pulmonale Metastasen

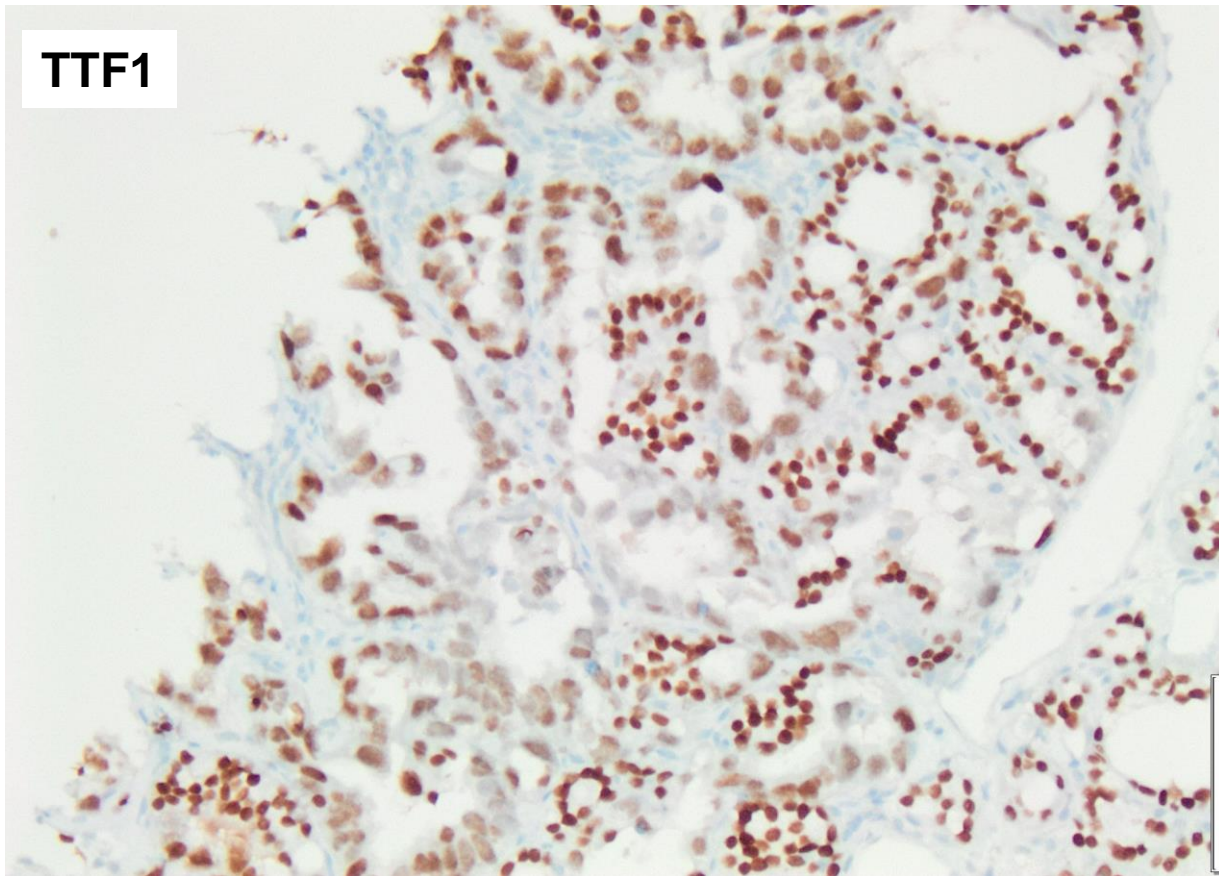
Nadelpunktion Schilddrüse







TTF1



Kasuistik 15-21

Welche Zusatzuntersuchungen beauftragen Sie?

Welche Diagnose stellen Sie?