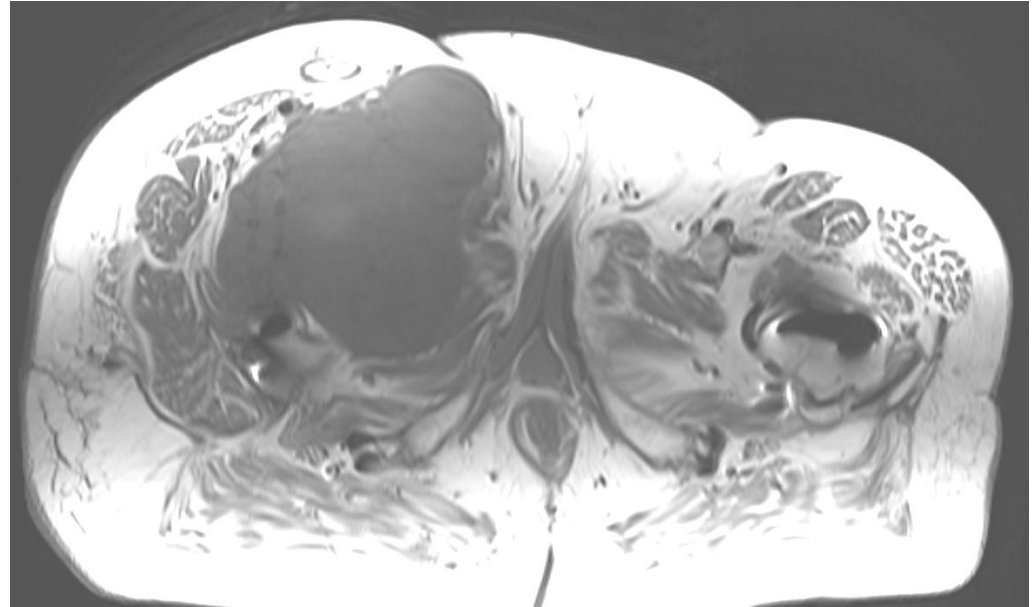


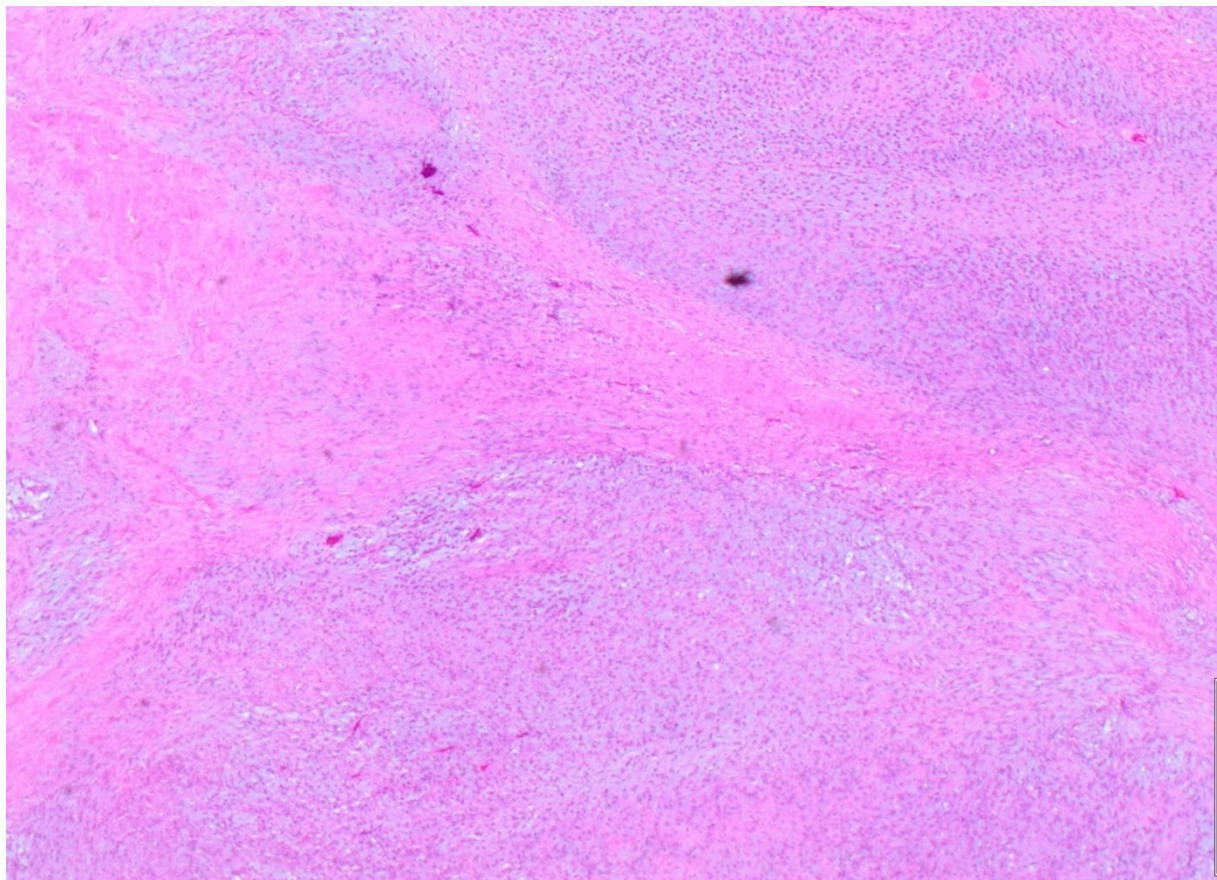
Kasuistik 16-21

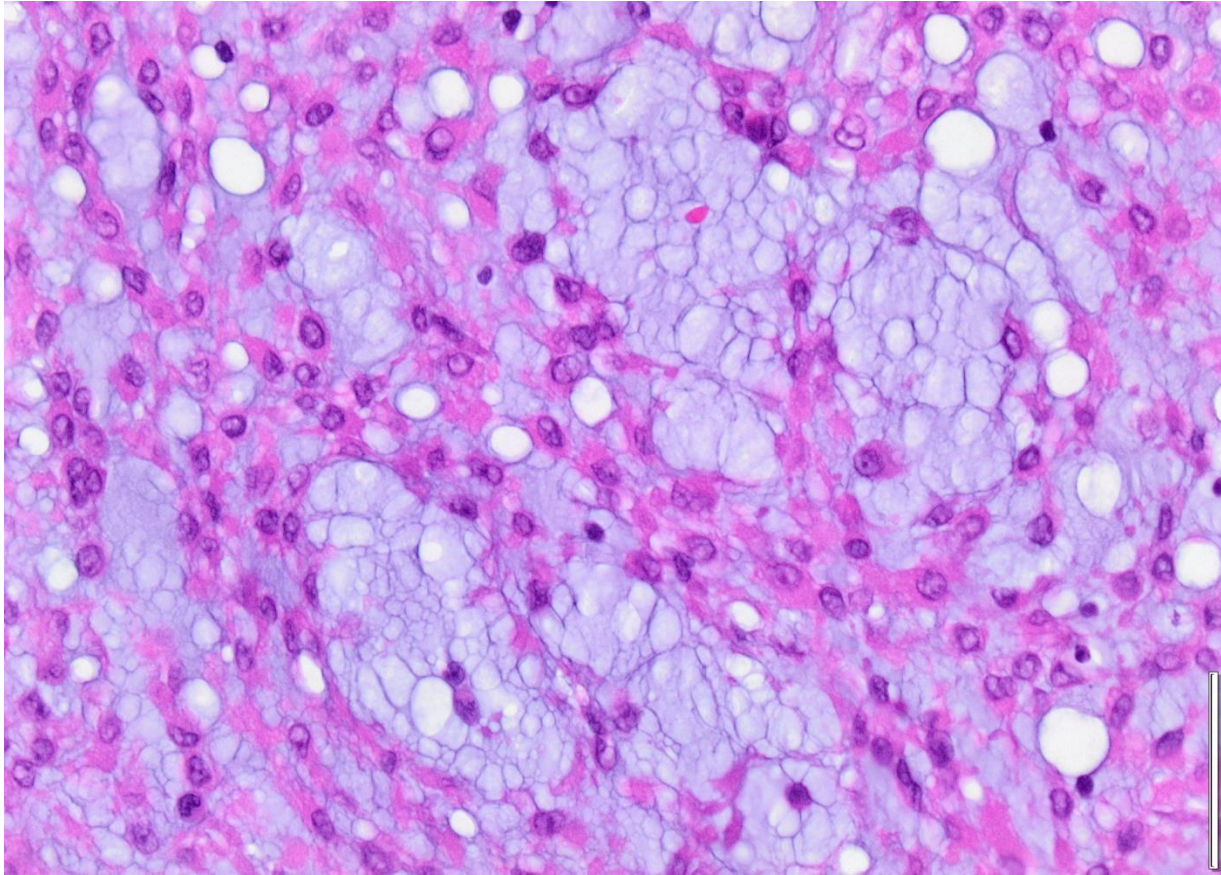
75-jähriger Mann

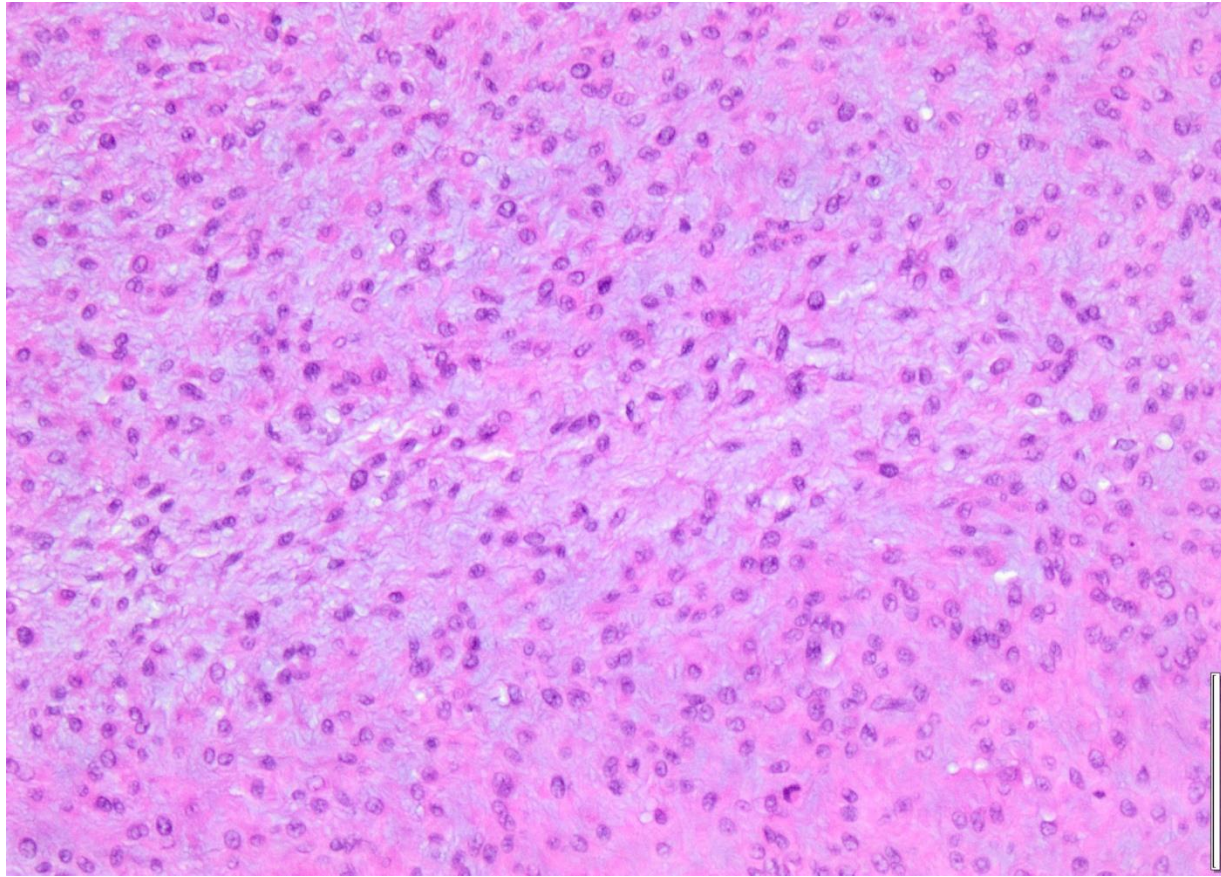
9 cm großer Tumor rechter OS

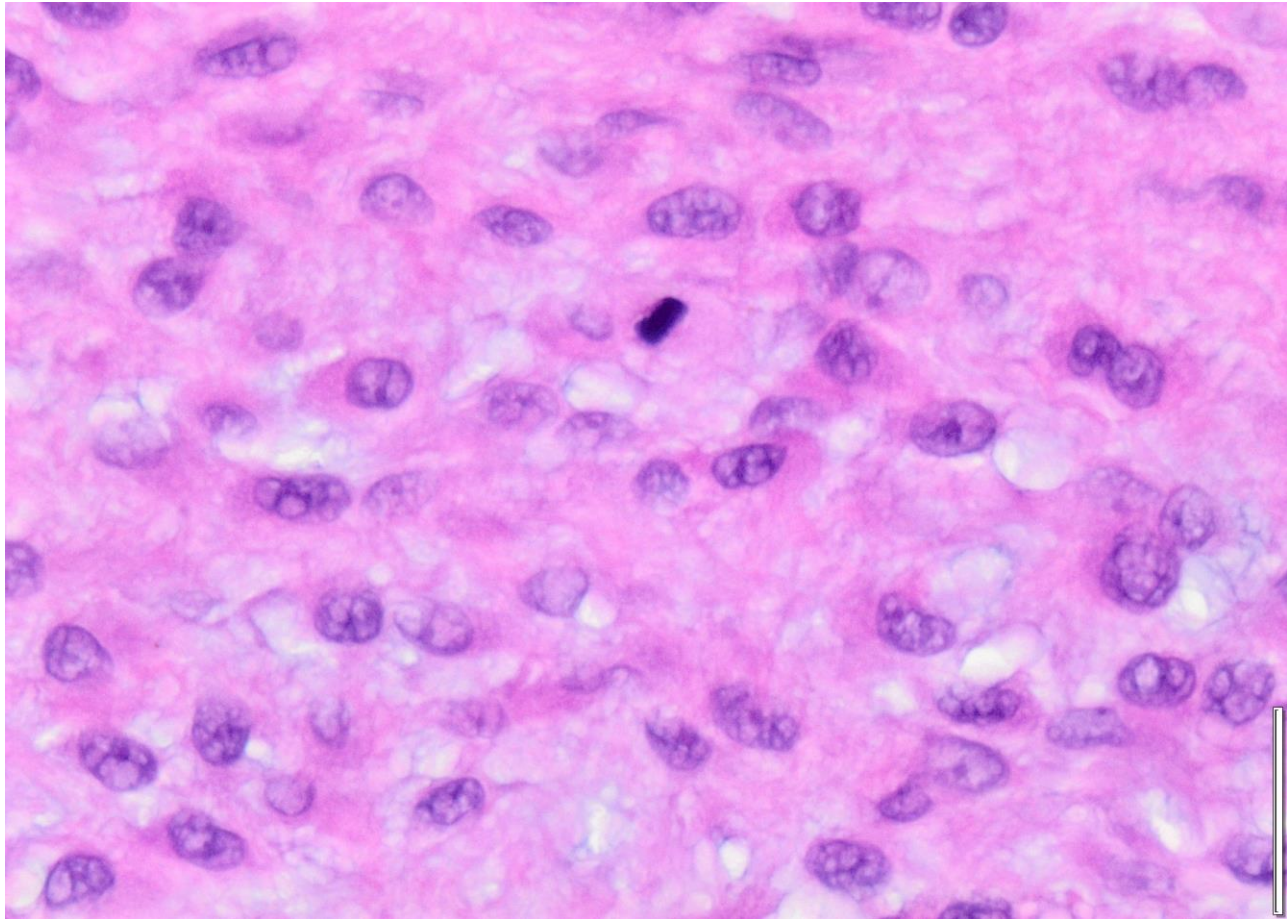
Resektion



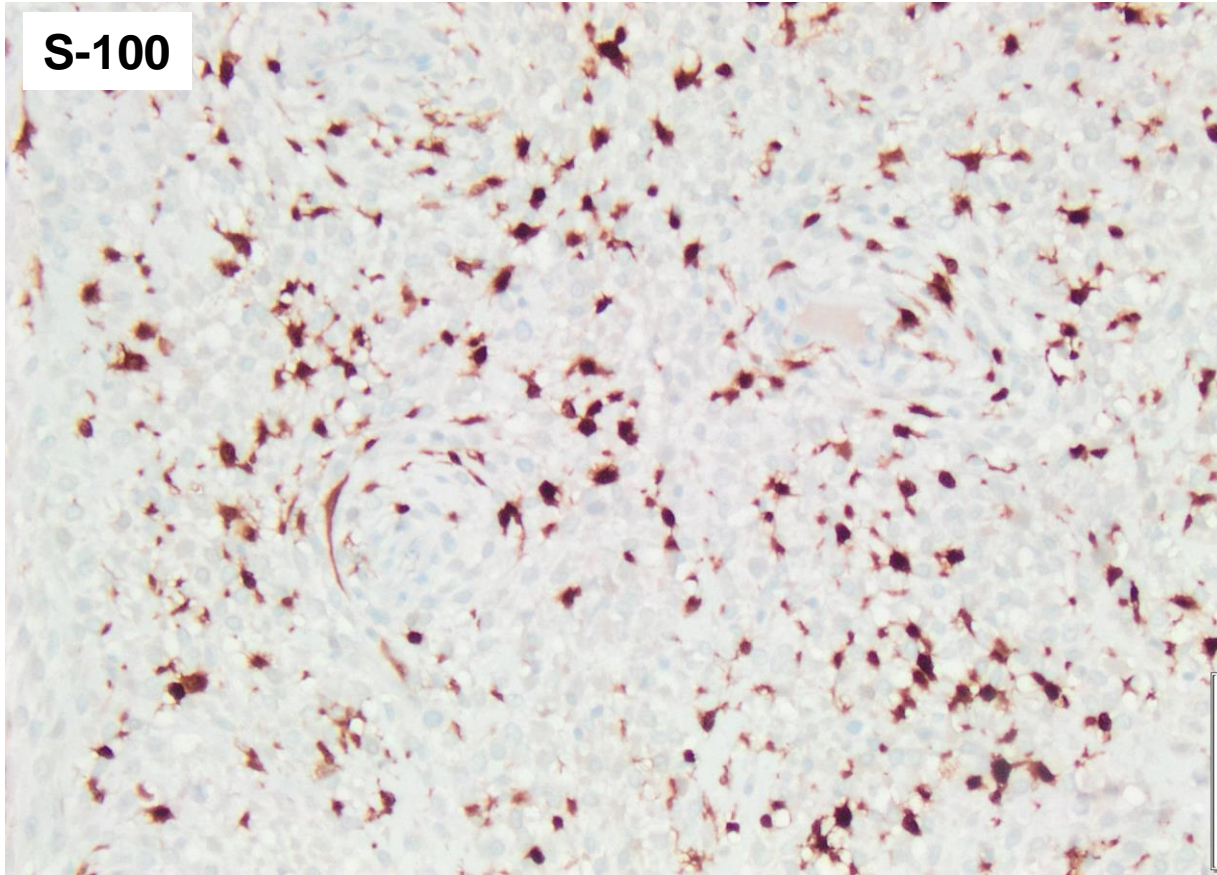








S-100



Kasuistik 16-21

Welche Zusatzuntersuchungen beauftragen Sie?

Welche Diagnose stellen Sie?