

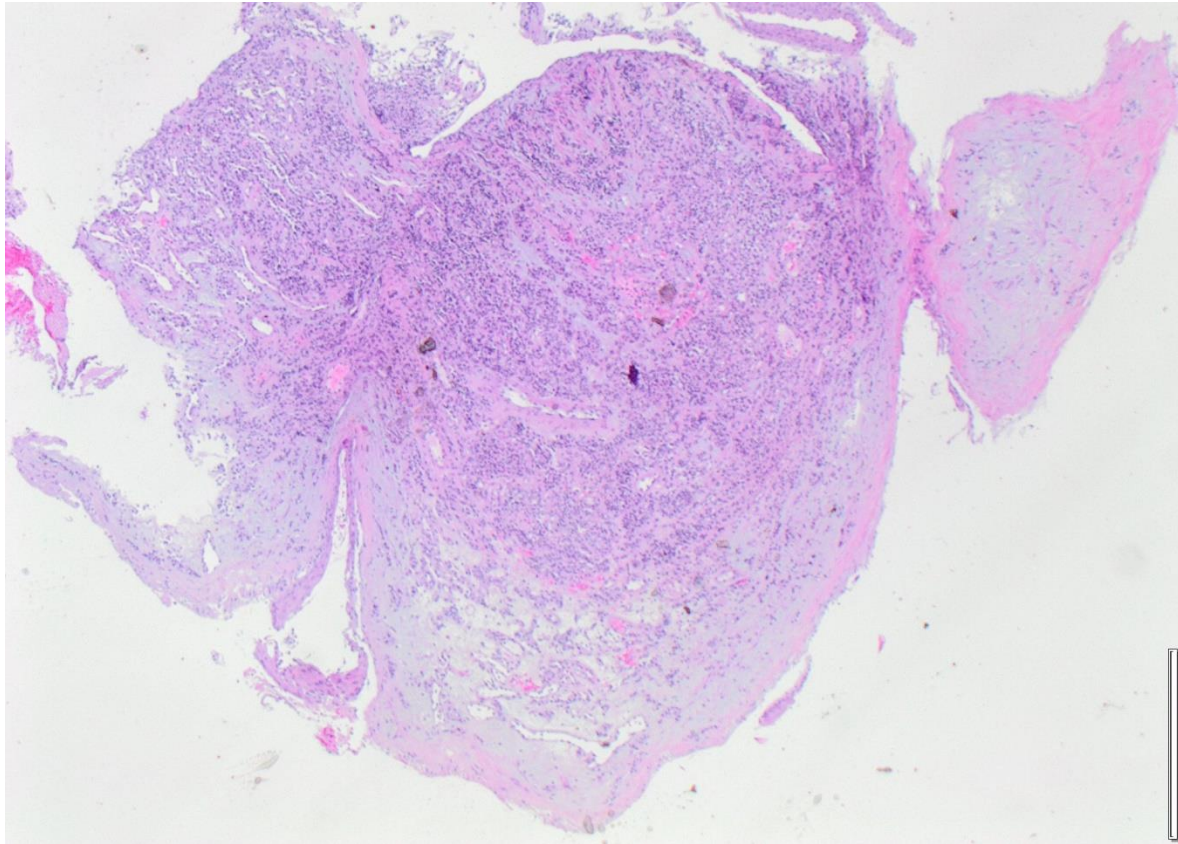
## Kasuistik 18-21

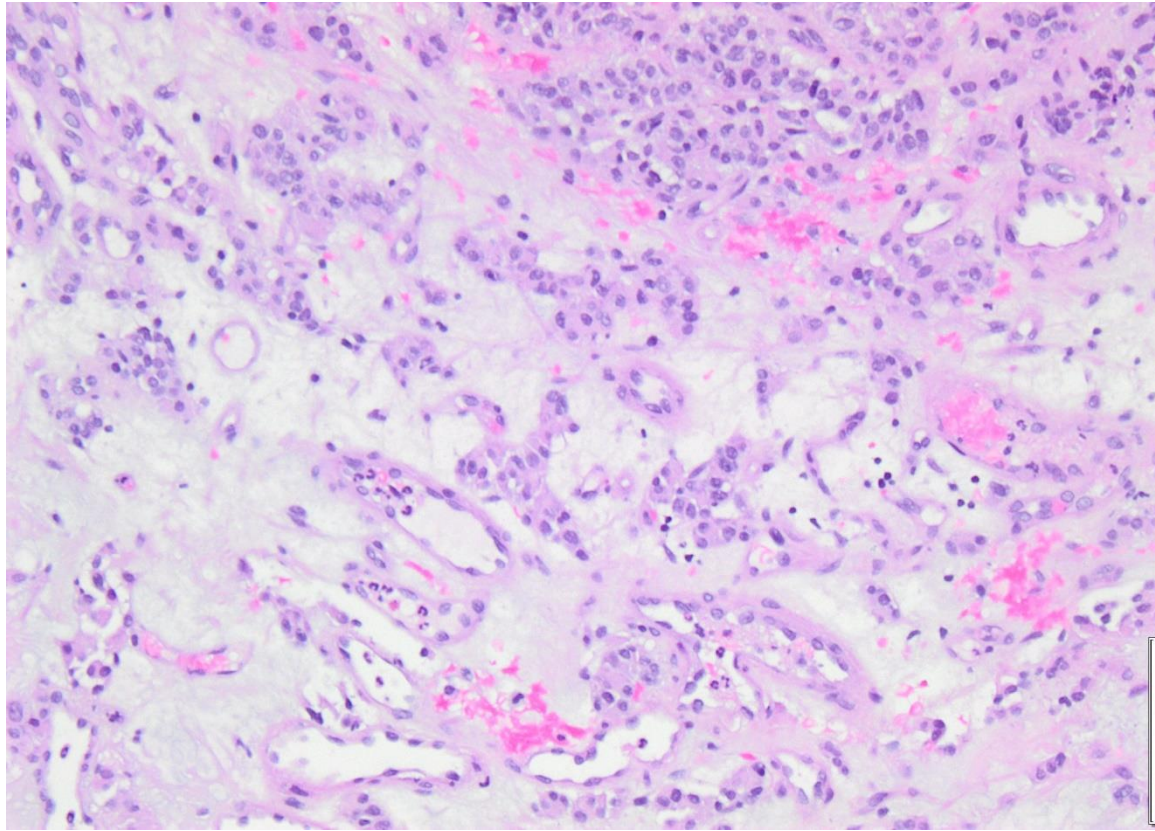
34-jährige Patientin,

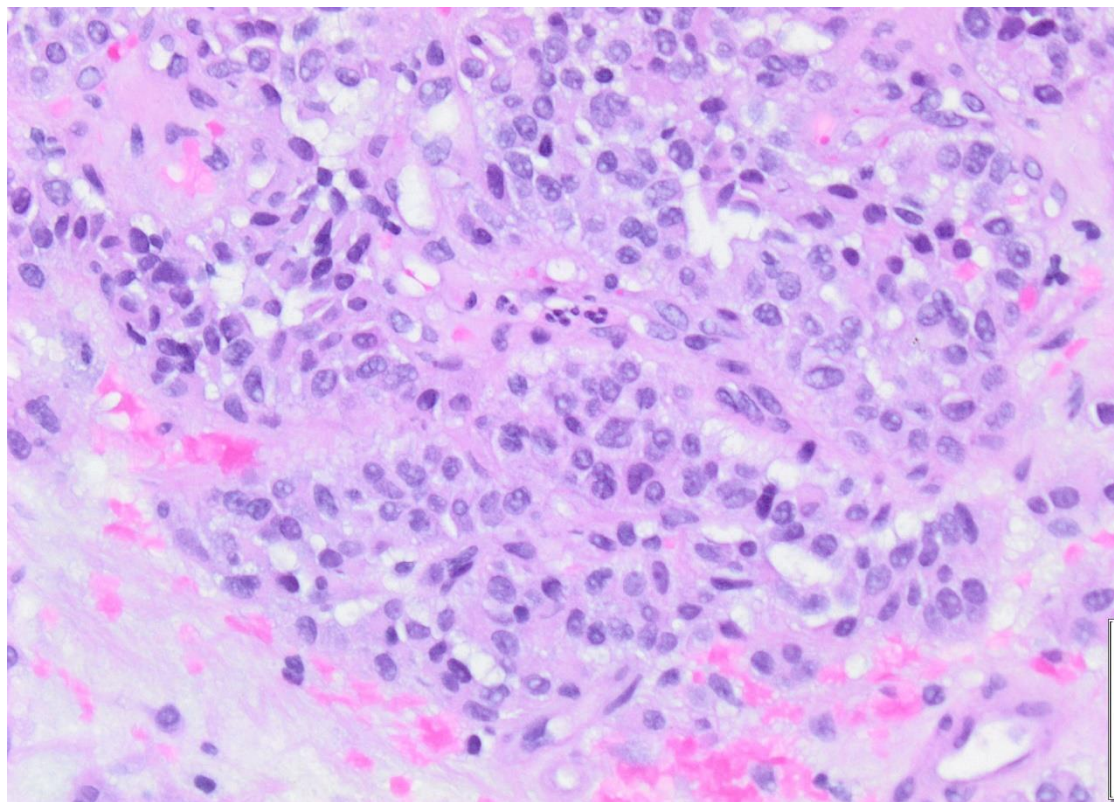
Z.n. Pneumonie

Fraglicher Tumor im Ostium des

Mittellappenbronchus

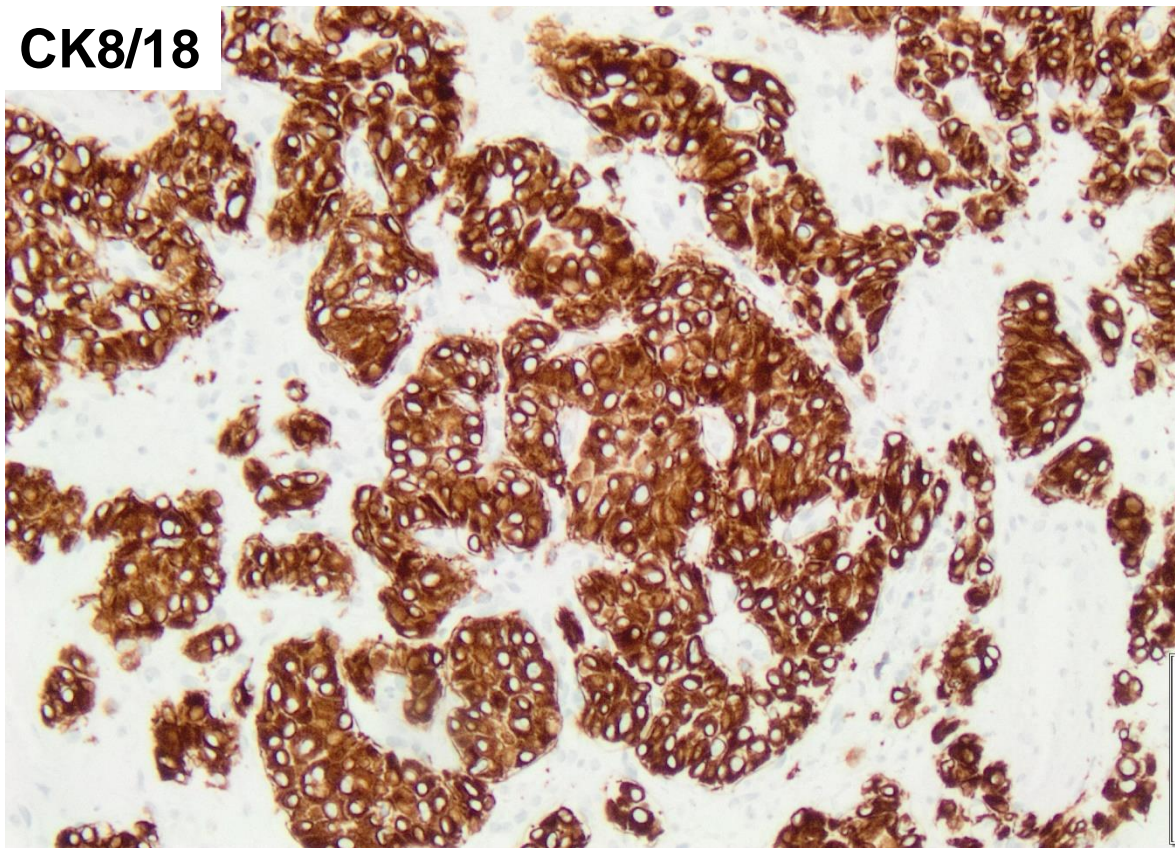








CK8/18



## Kasuistik 18-21

Welche Zusatzuntersuchungen beauftragen Sie?

Welche Diagnose stellen Sie?