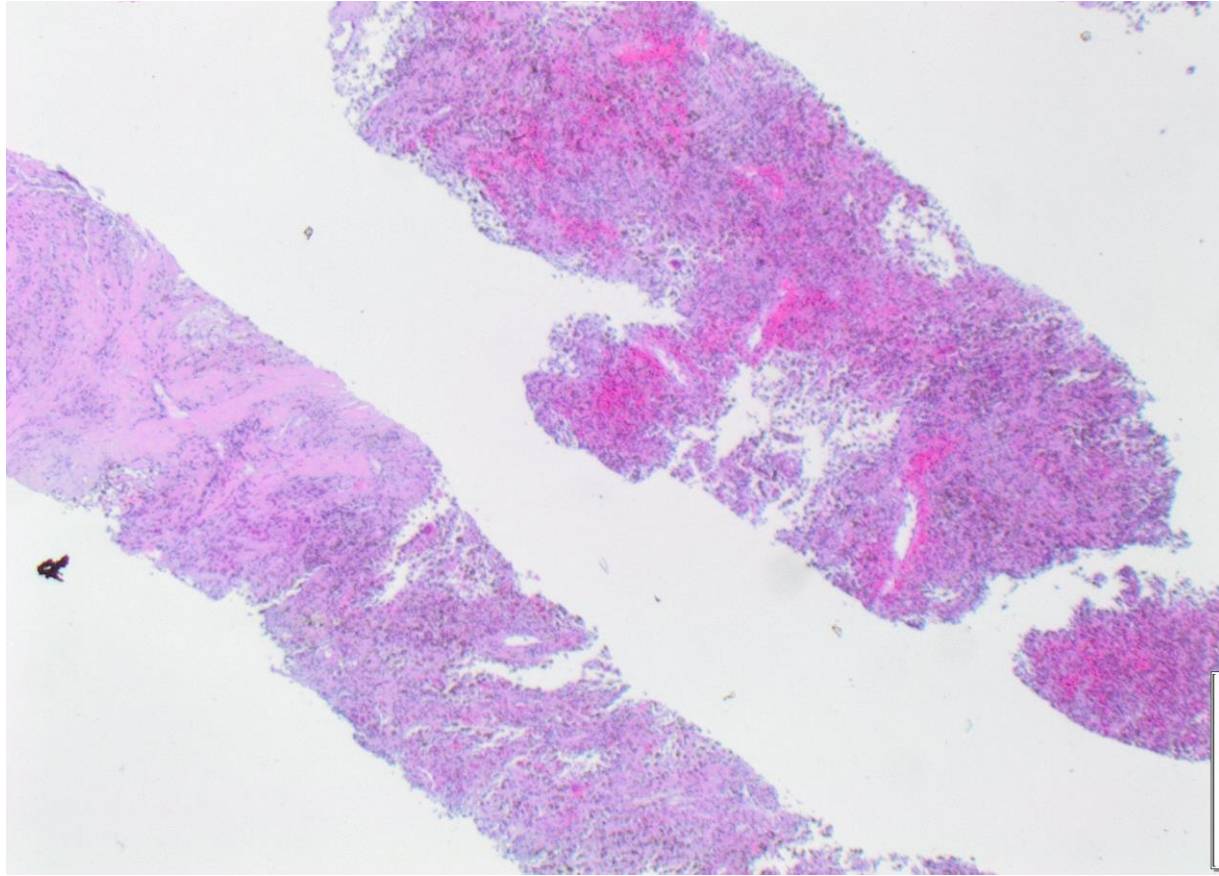
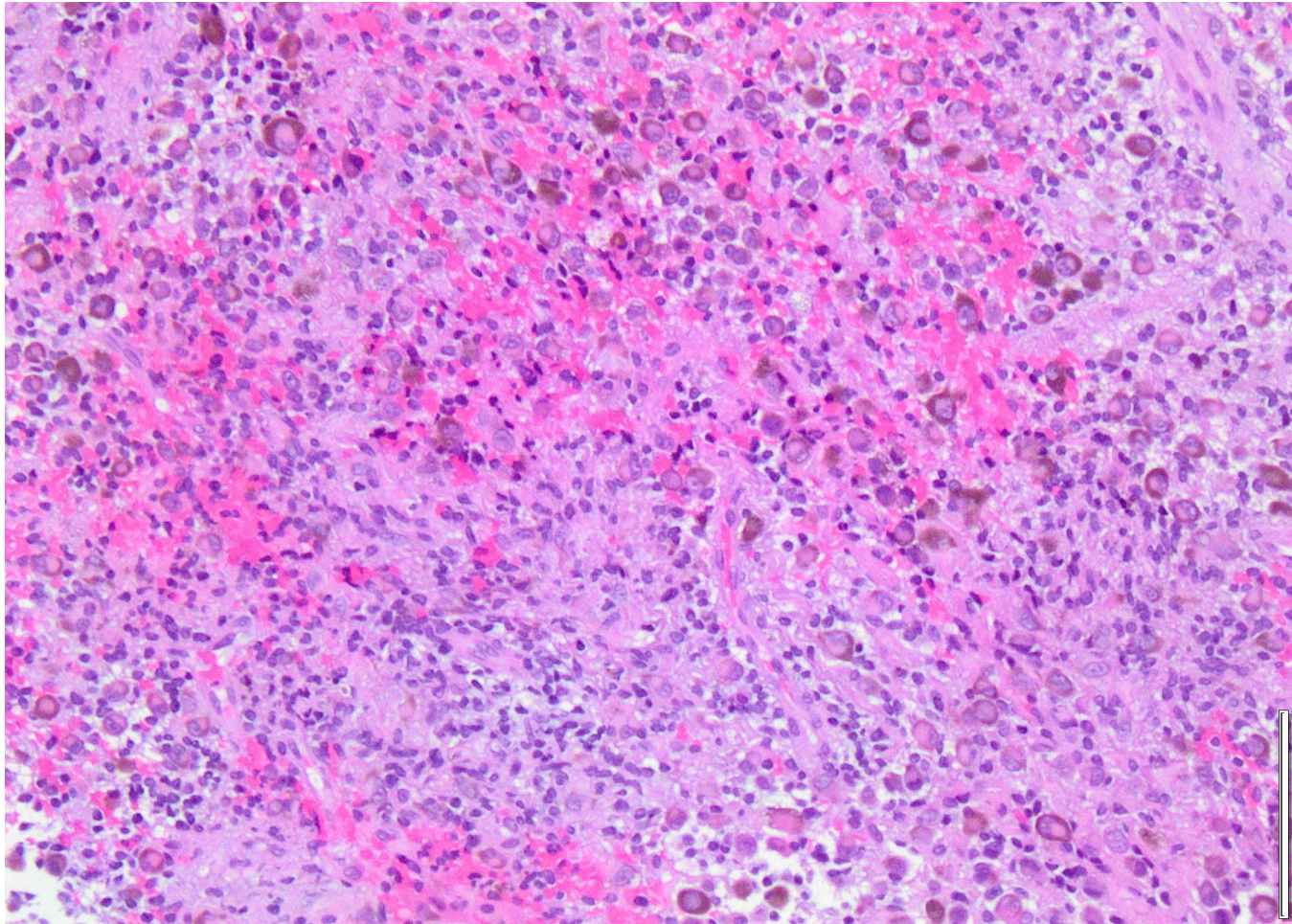
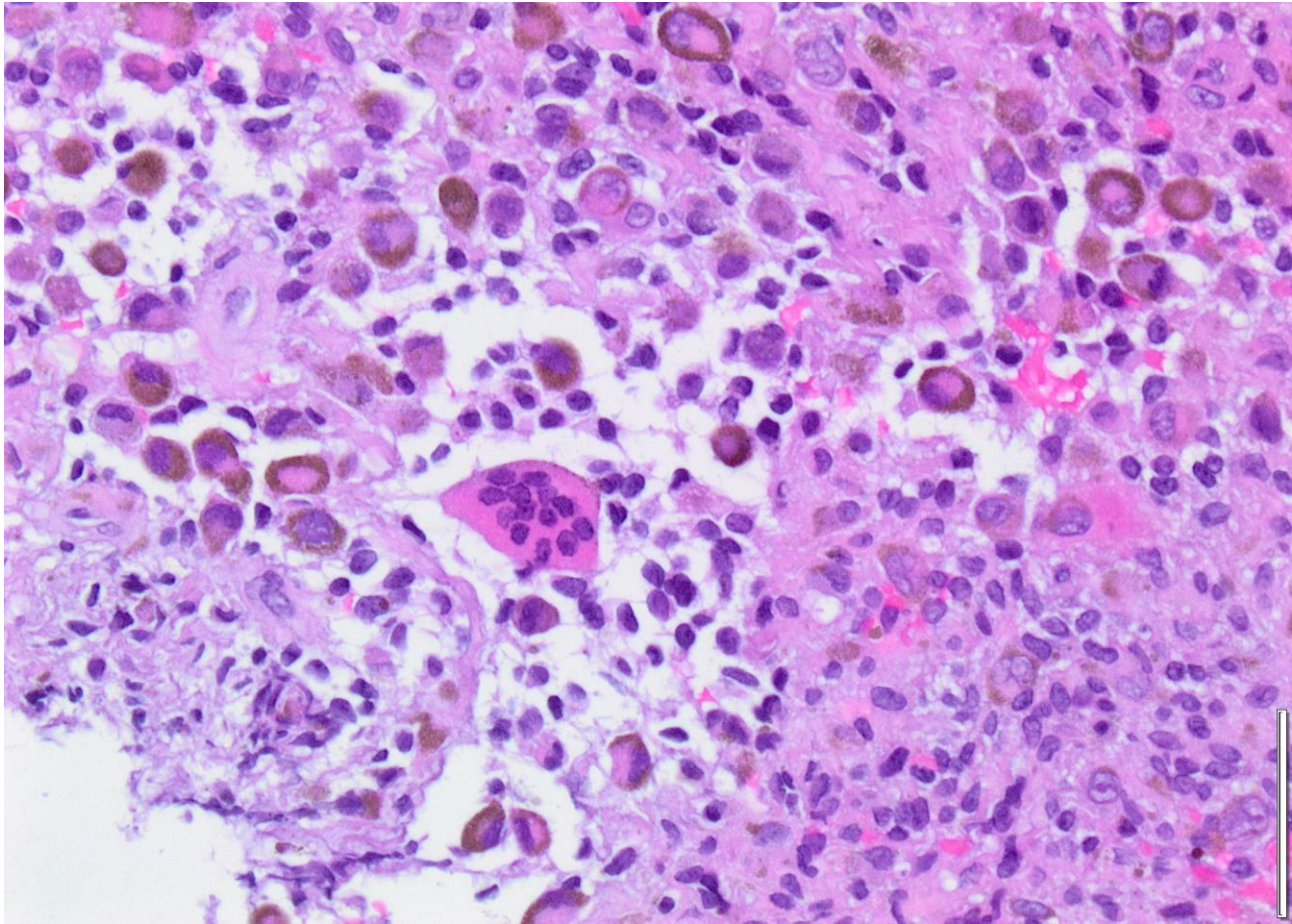


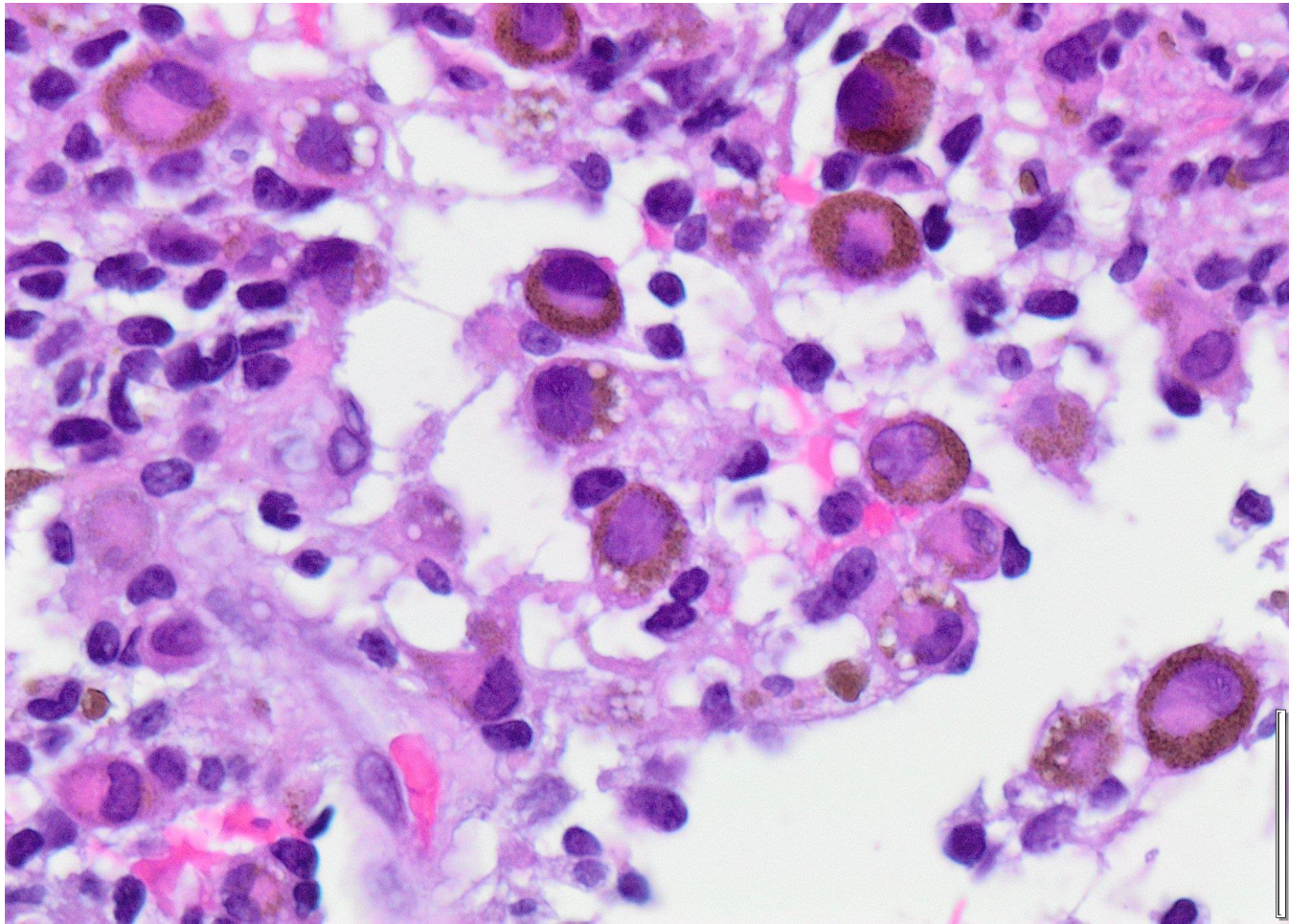
Kasuistik 19-21

34-jährige Patientin,
Tumor linke Wade
epifaszial, sehnennah









Kasuistik 19-21

Welche Zusatzuntersuchungen beauftragen Sie?

Welche Diagnose stellen Sie?