

Kasuistik 20-21

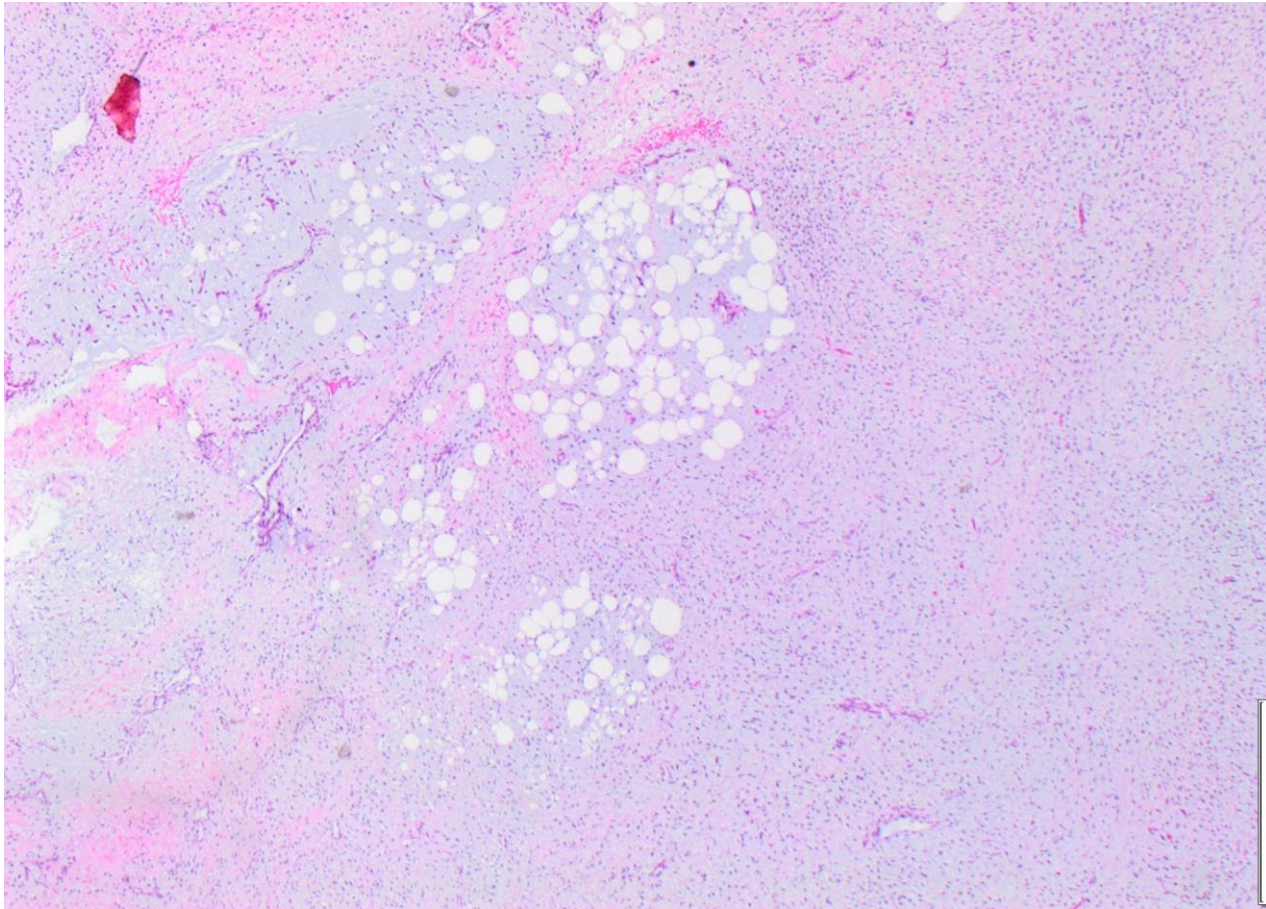
4 Monate alter männlicher

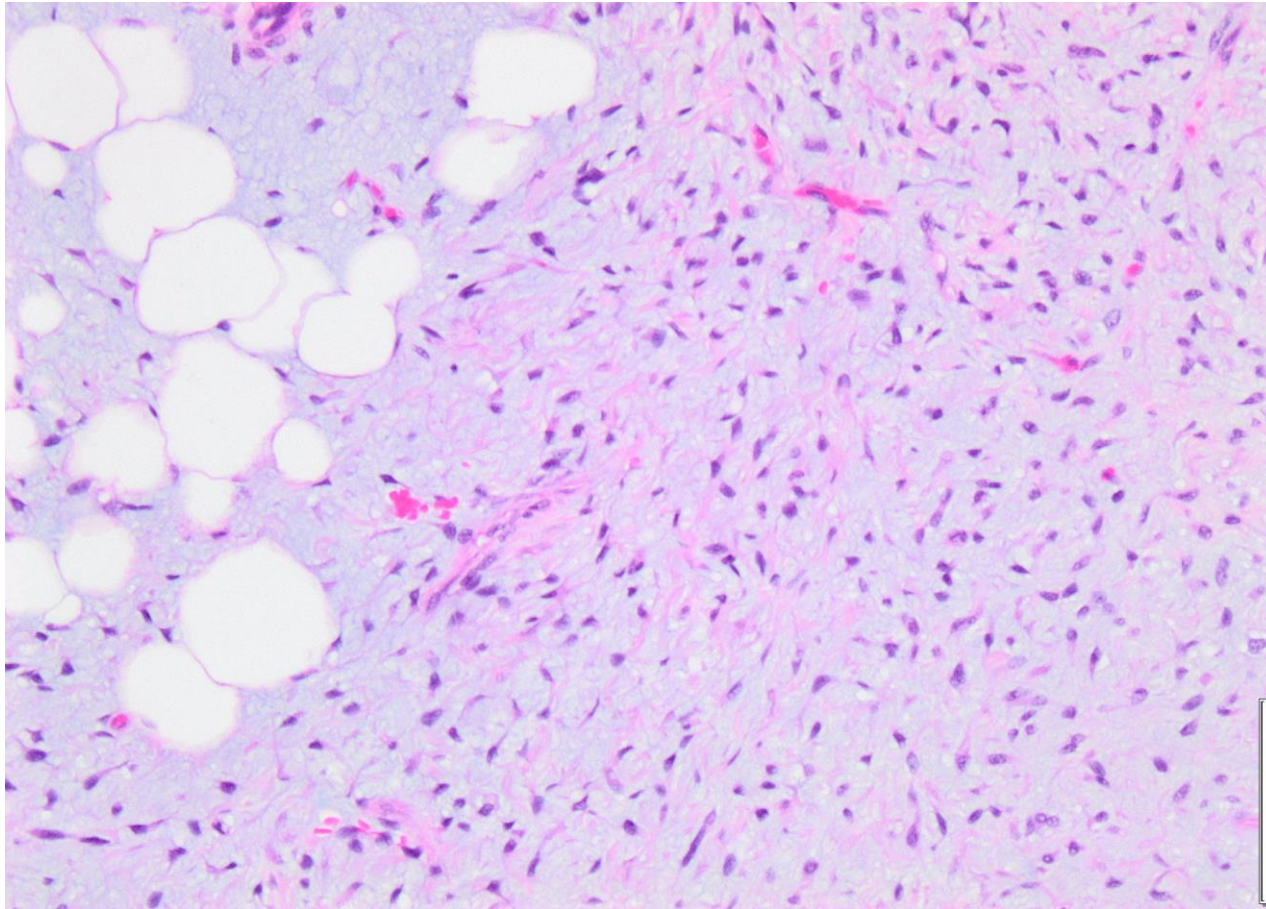
Säugling

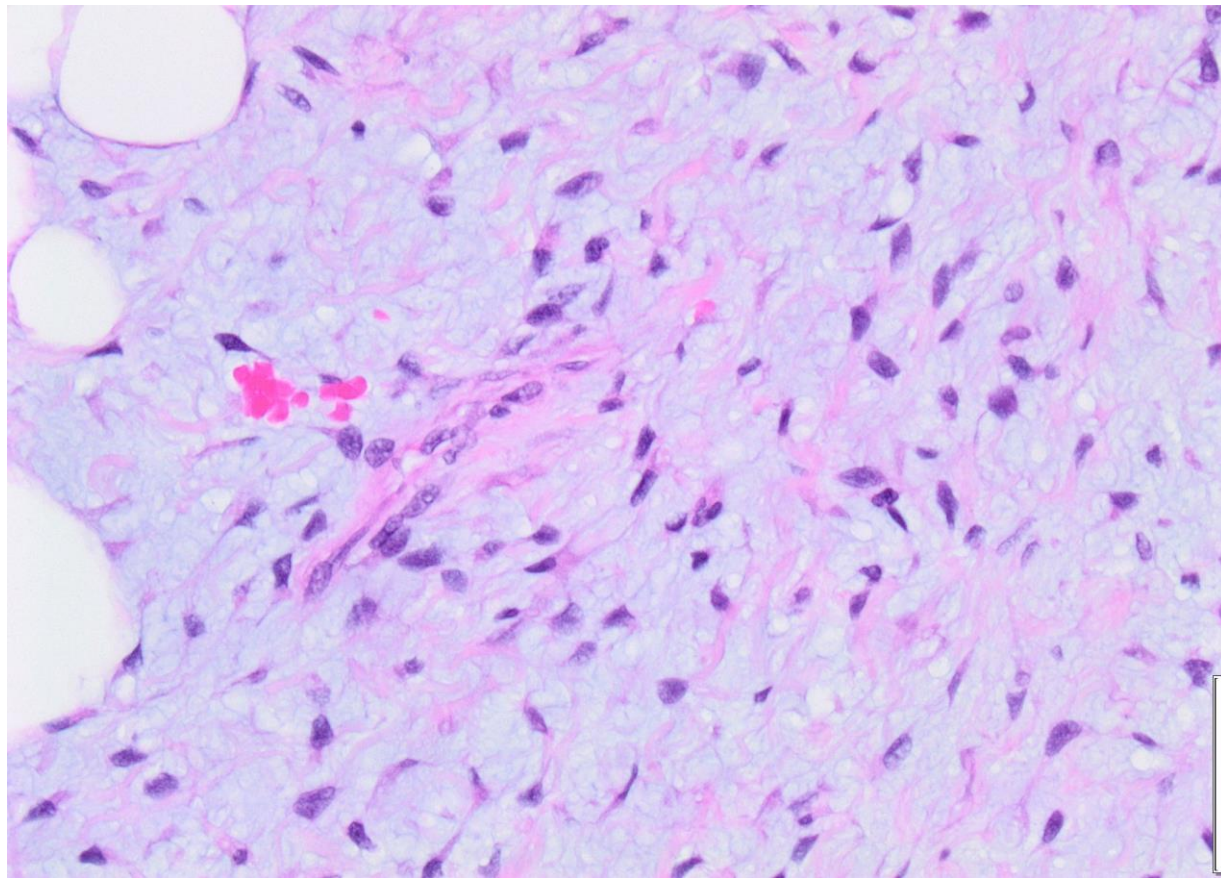
3 cm großer Tumor

intramuskulär

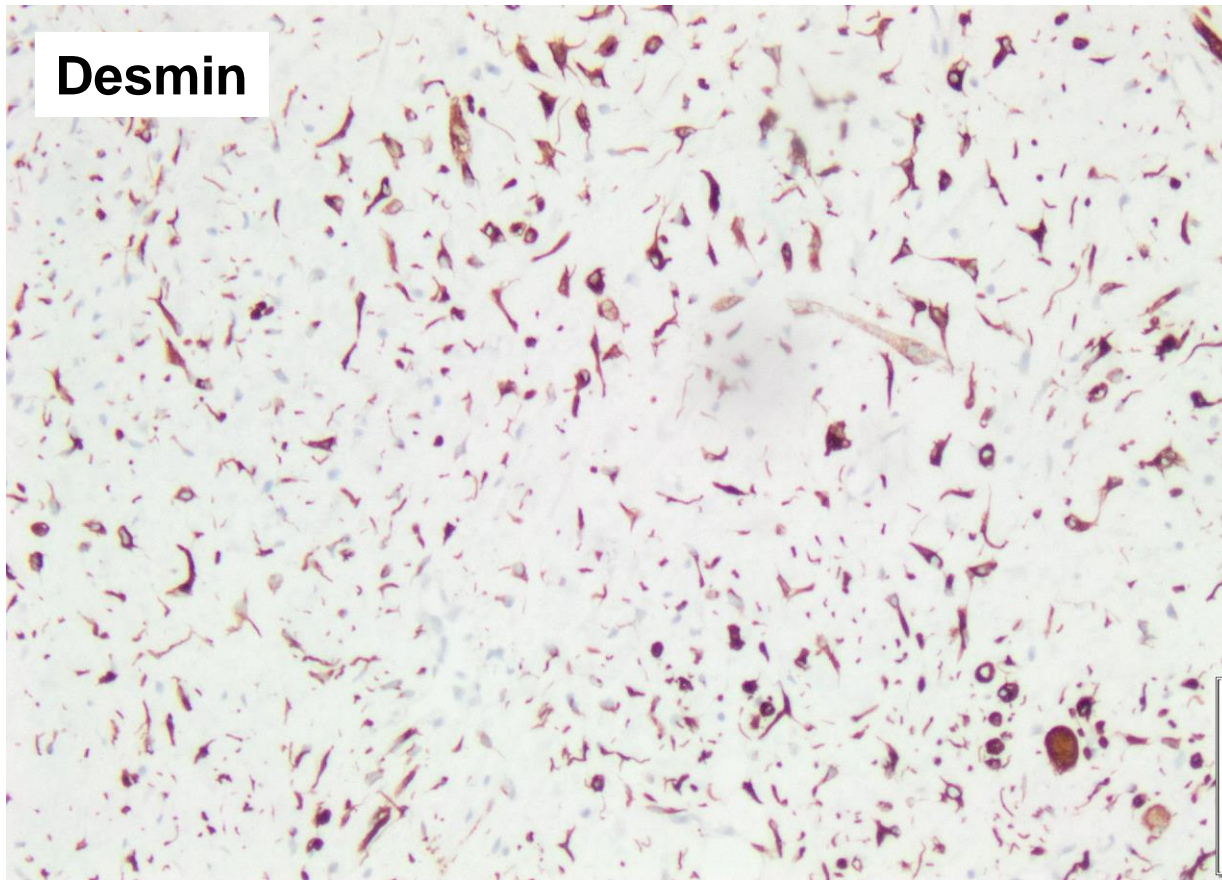
rechter Oberschenkel







Desmin



CD56



Kasuistik 20-21

Welche Zusatzuntersuchungen beauftragen Sie?

Welche Diagnose stellen Sie?