

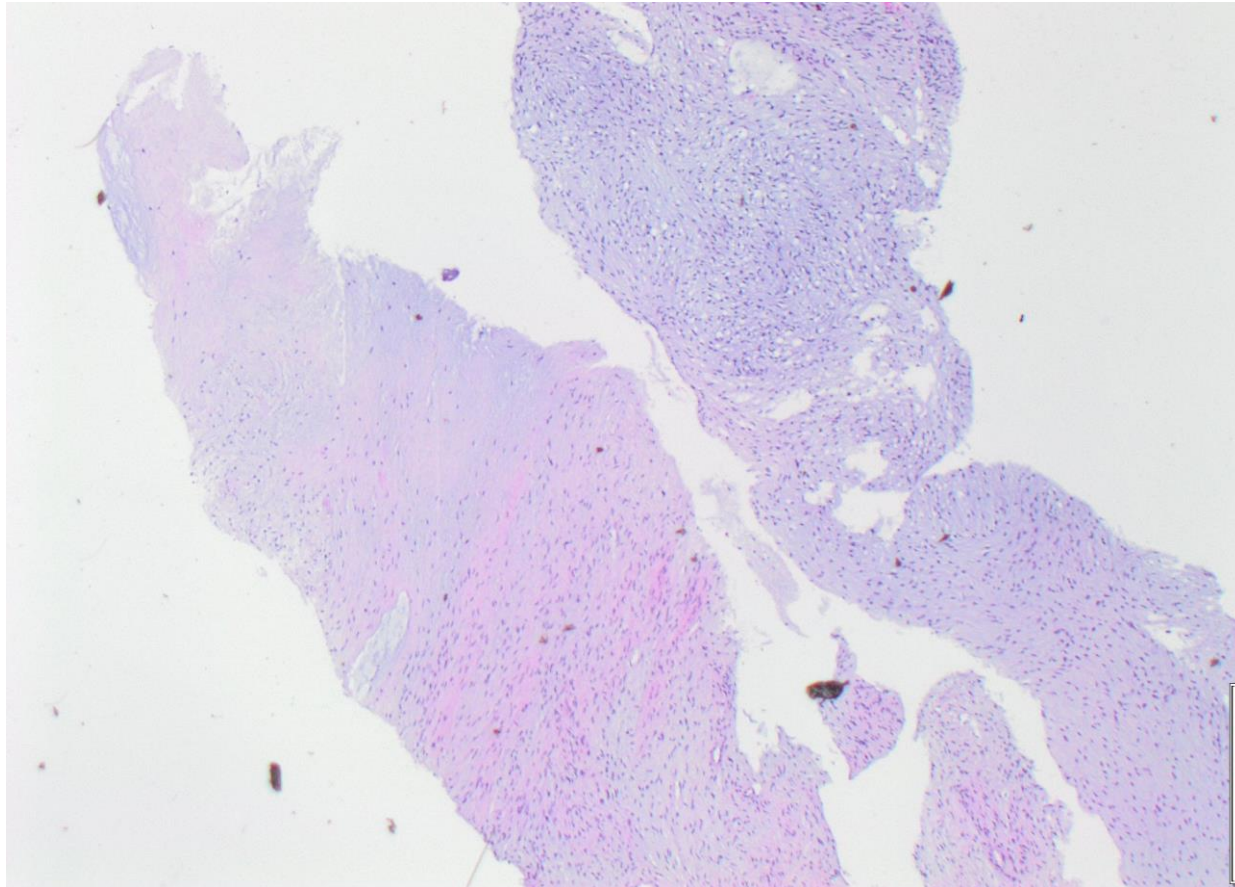
## Kasuistik 21-21

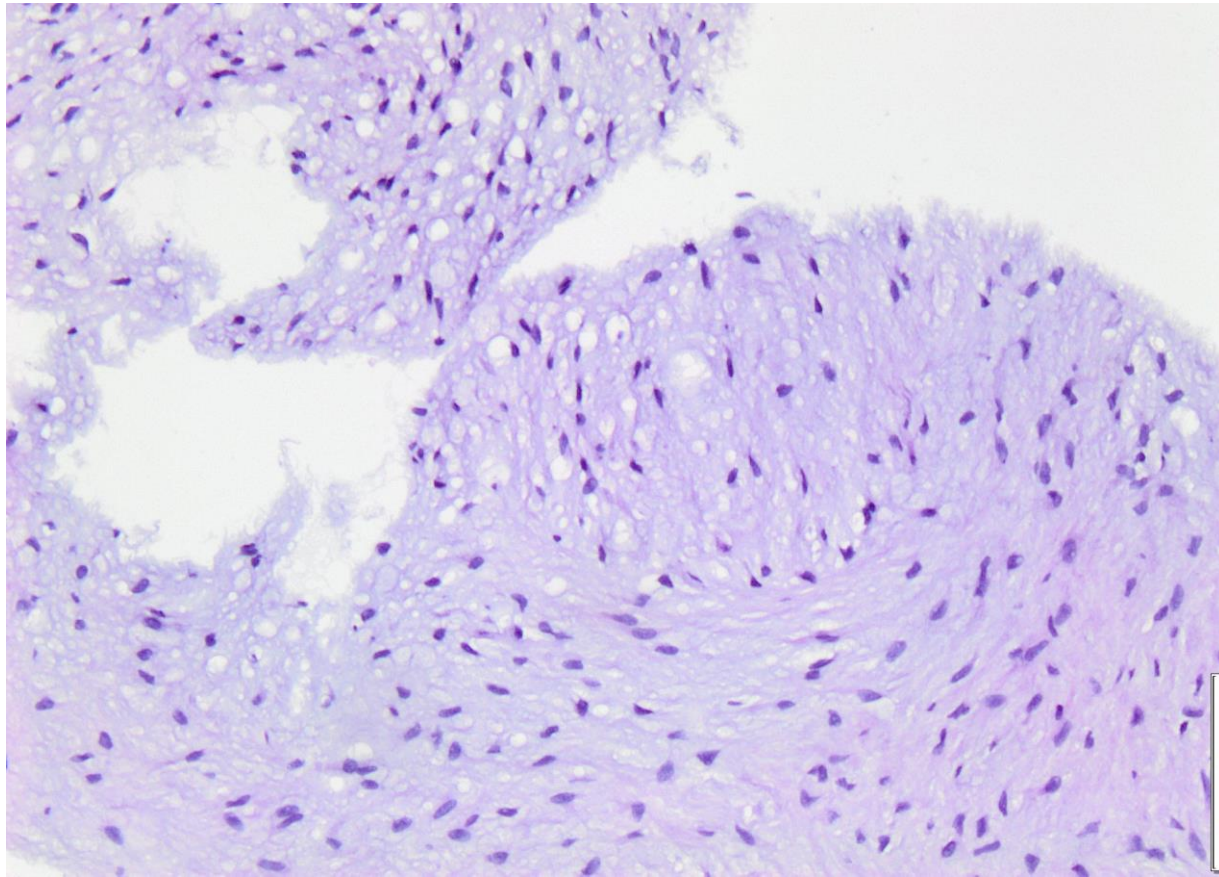
42-jährige Frau

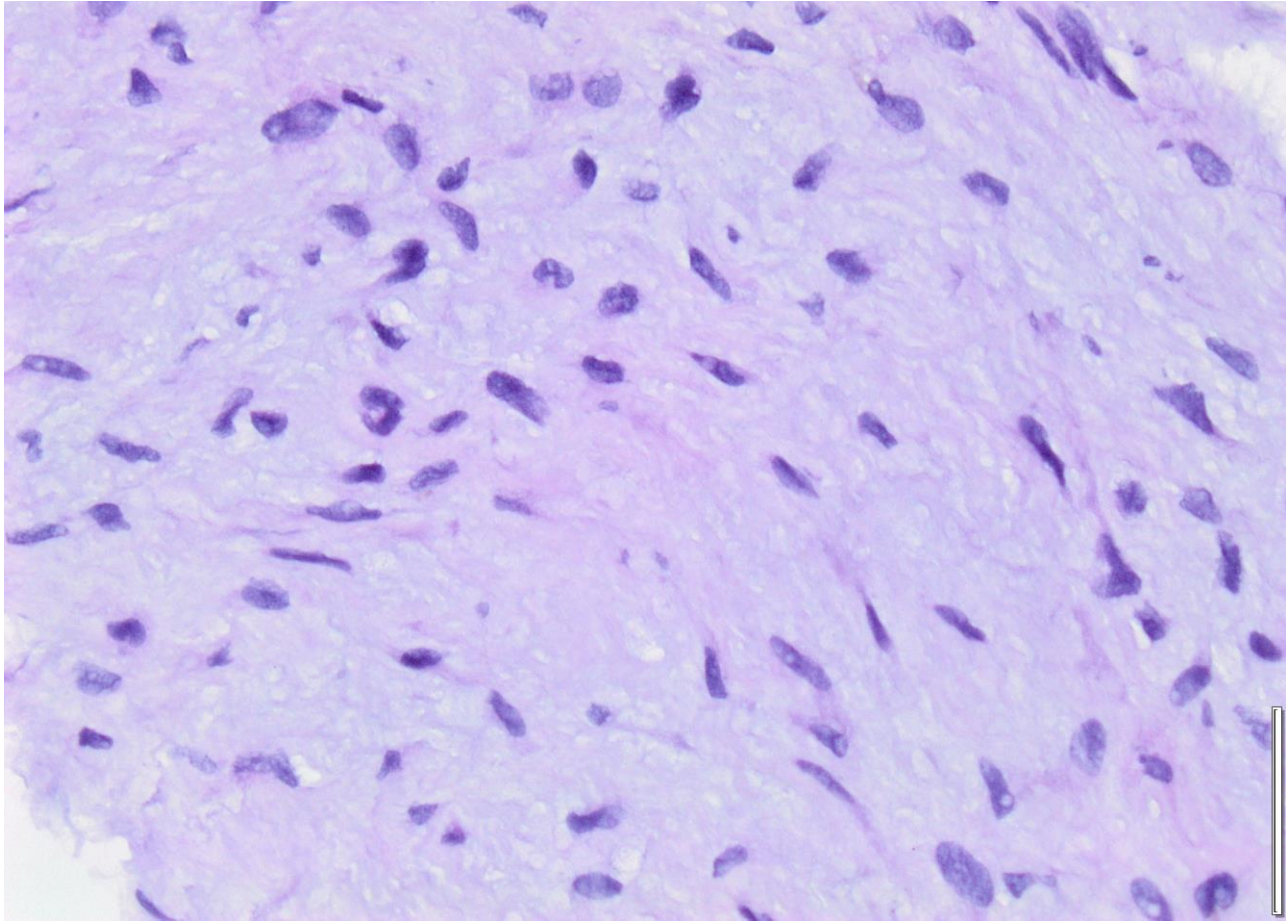
5 cm großer Tumor

intramuskulär

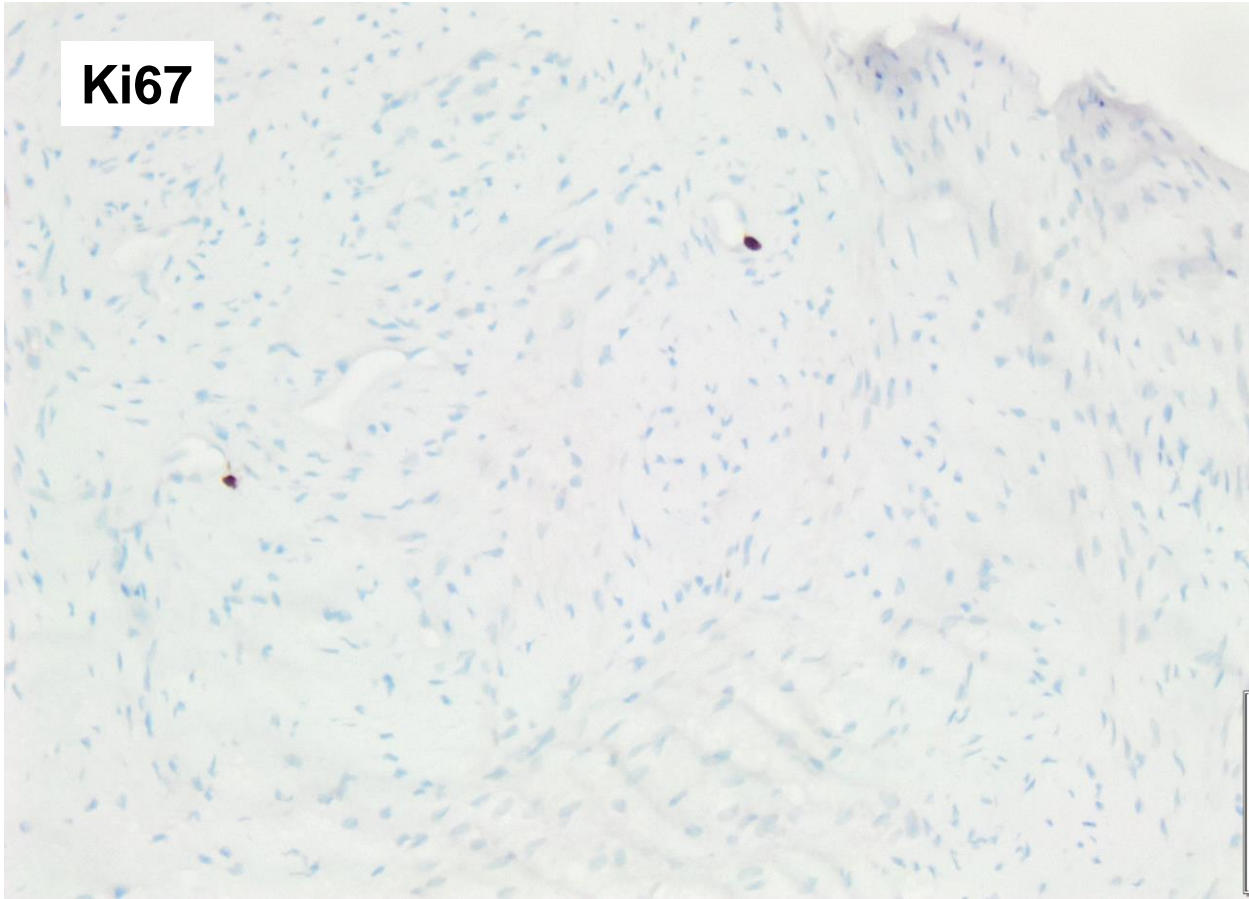
linker Oberschenkel



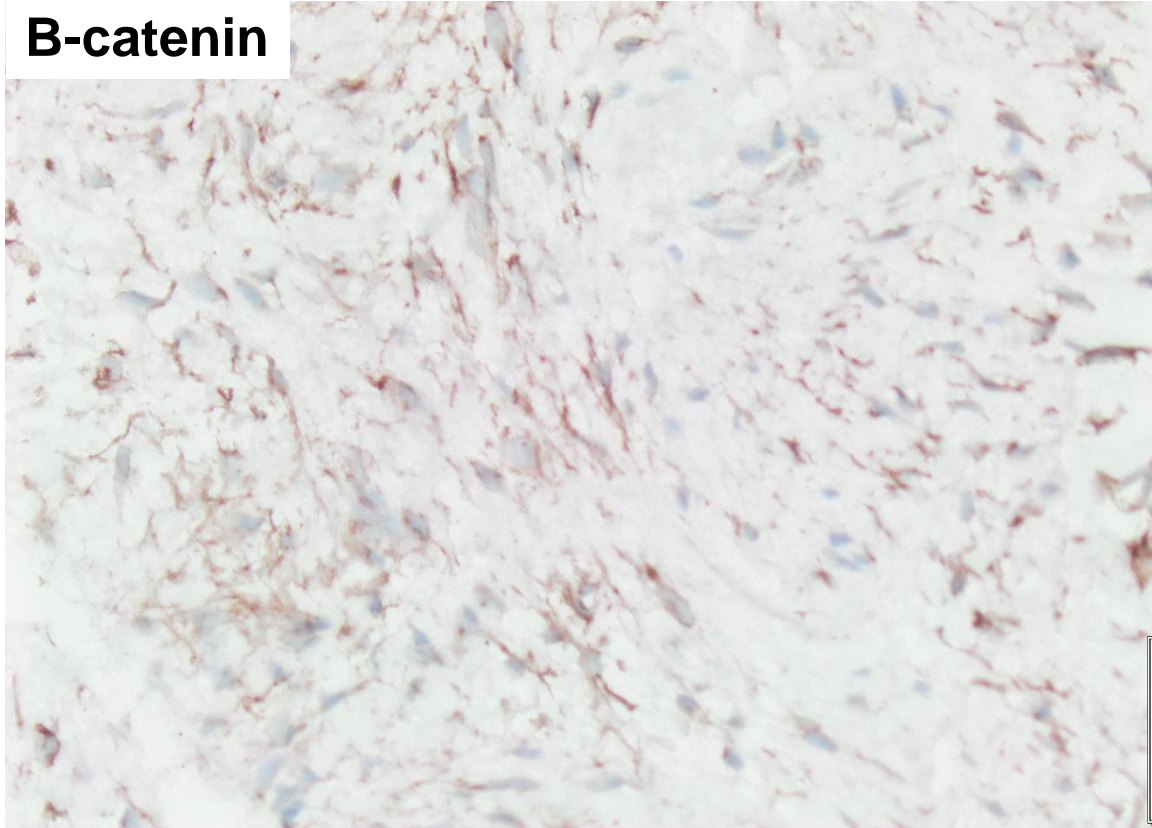




**Ki67**



## B-catenin



## Kasuistik 21-21

Welche Zusatzuntersuchungen beauftragen Sie?

Welche Diagnose stellen Sie?