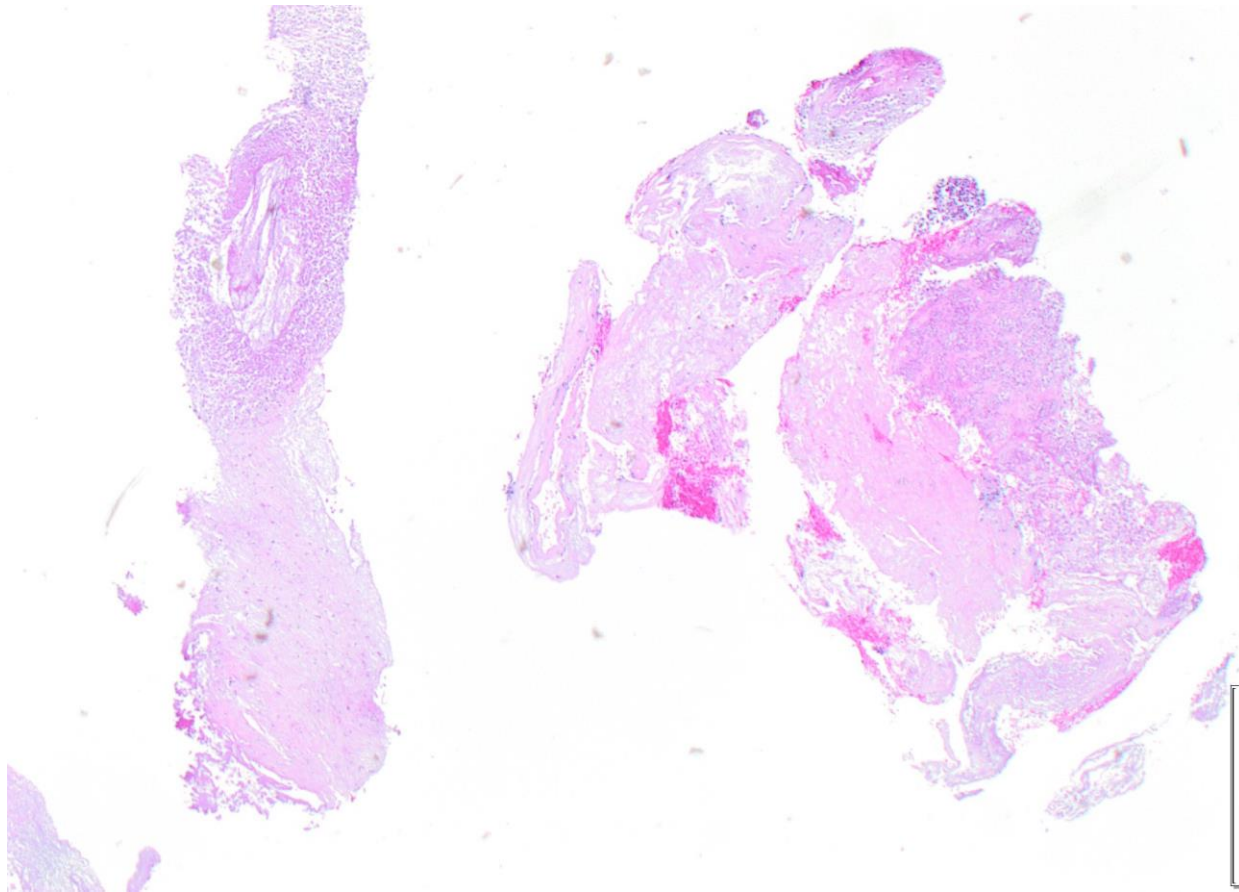


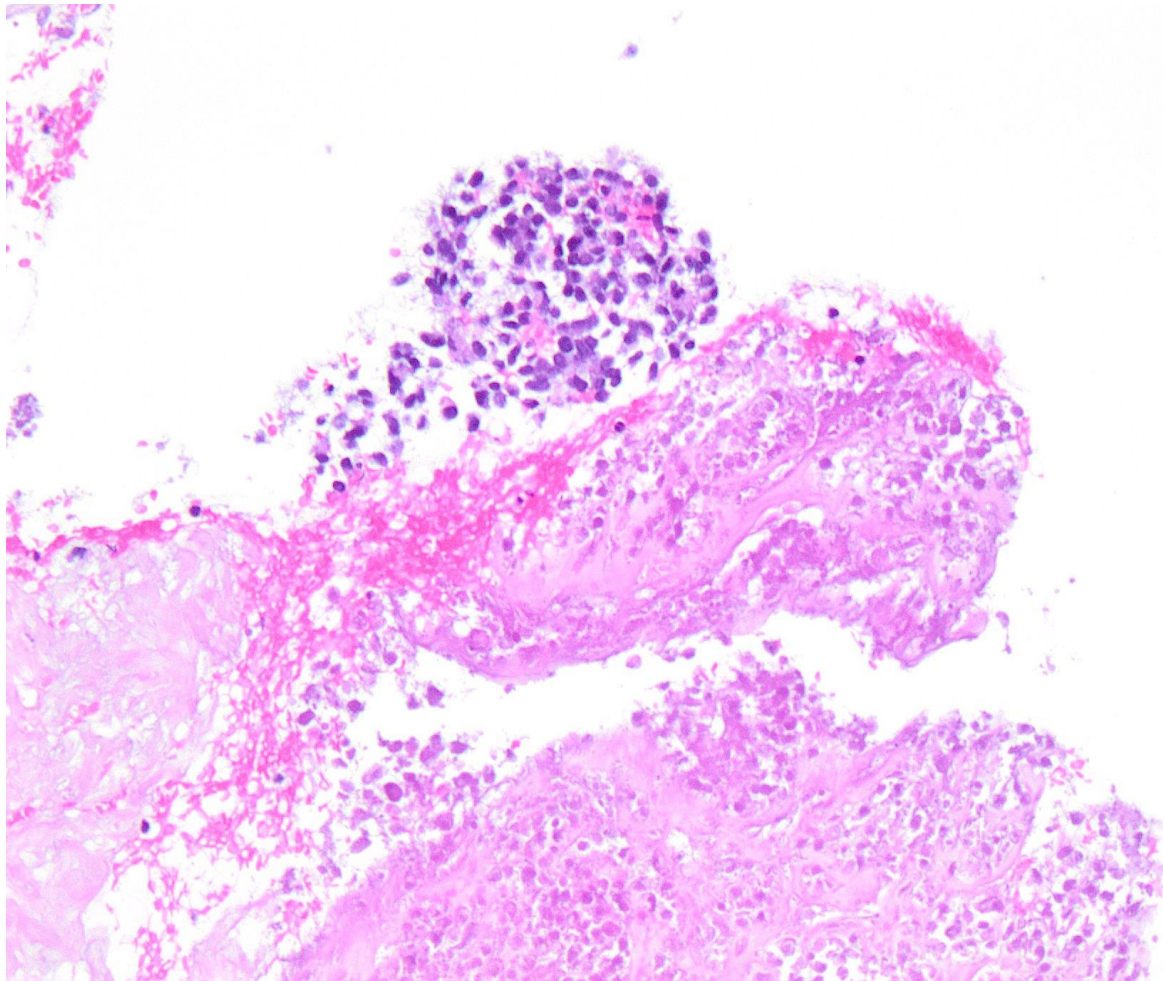
## Kasuistik 23-21

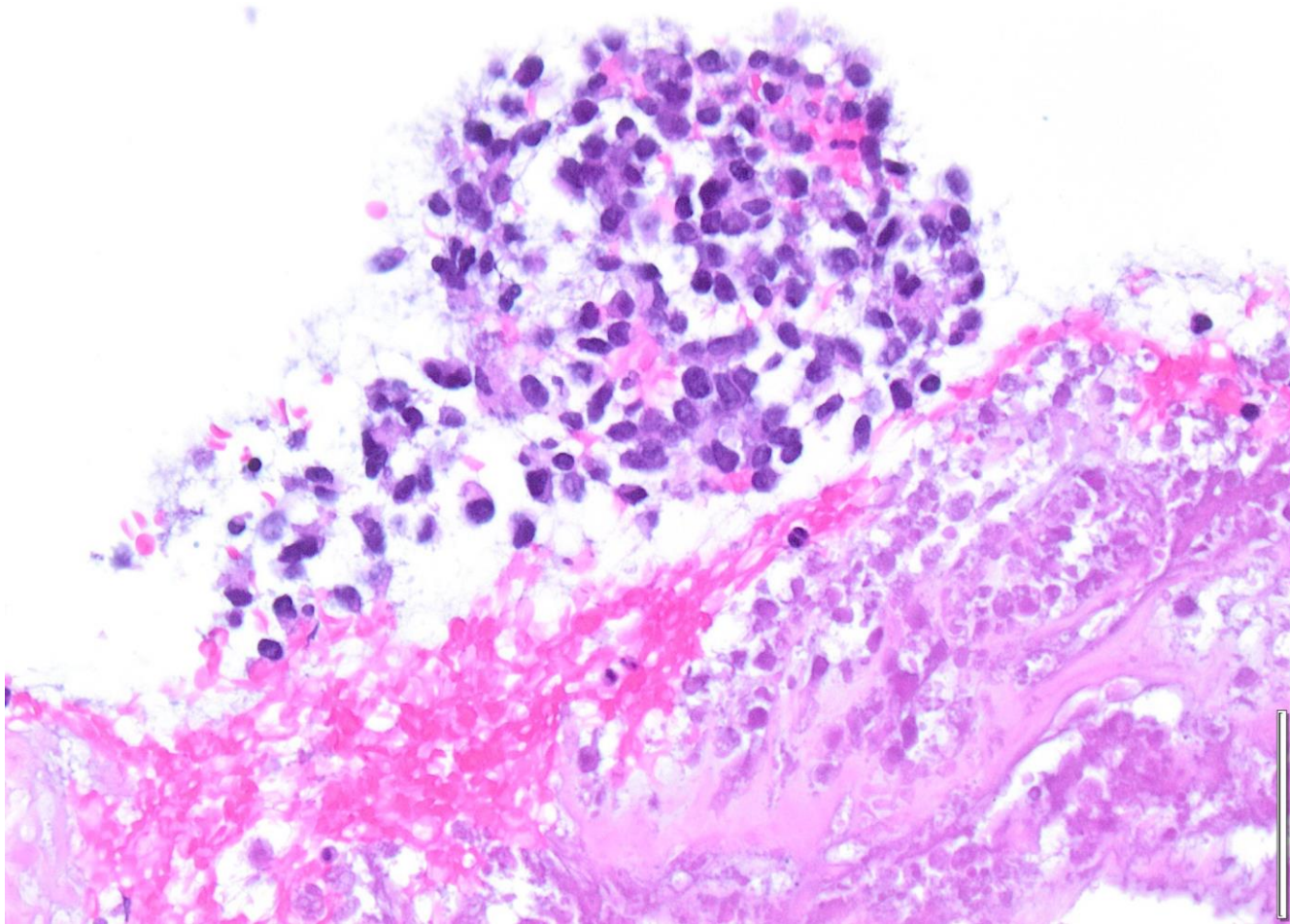
23-jährige Frau

5 cm großer Tumor

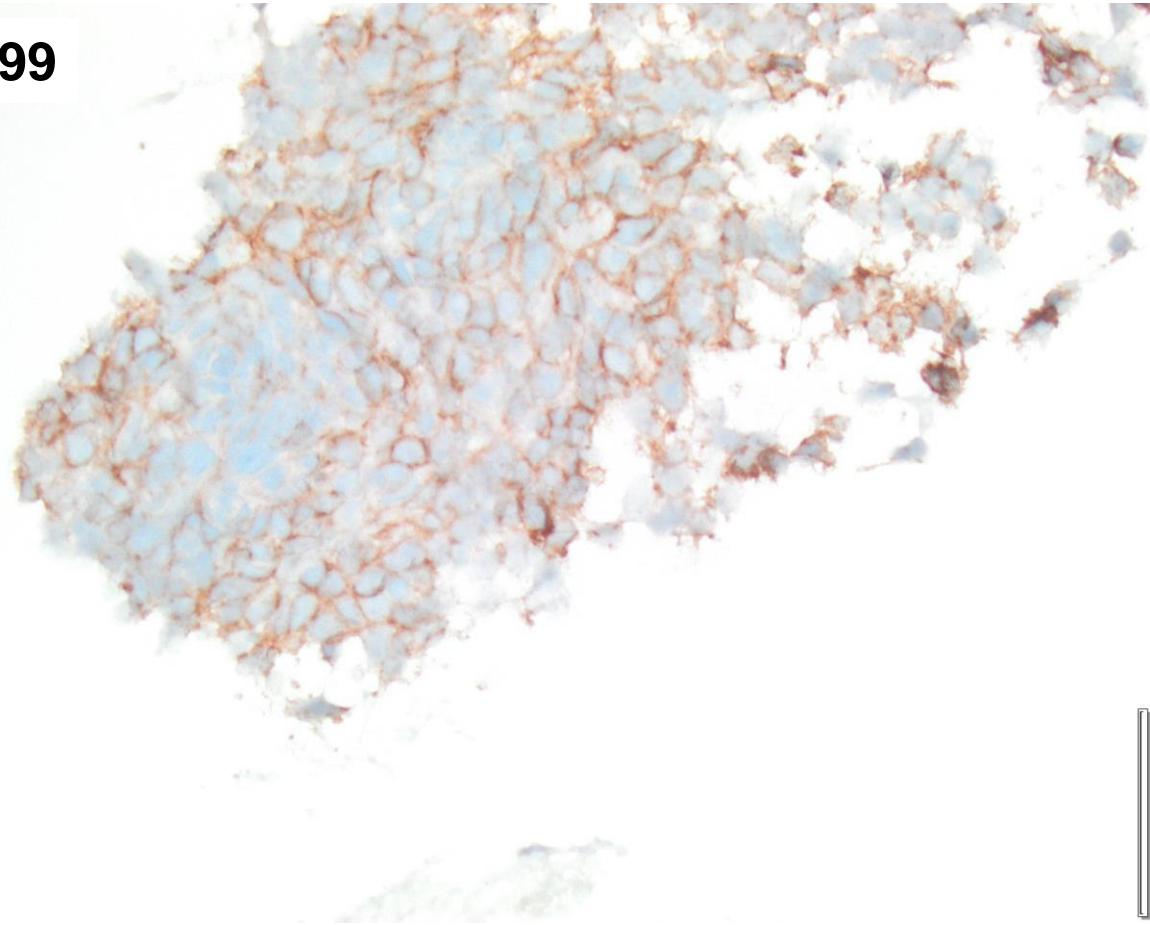
Unterarmmuskulatur



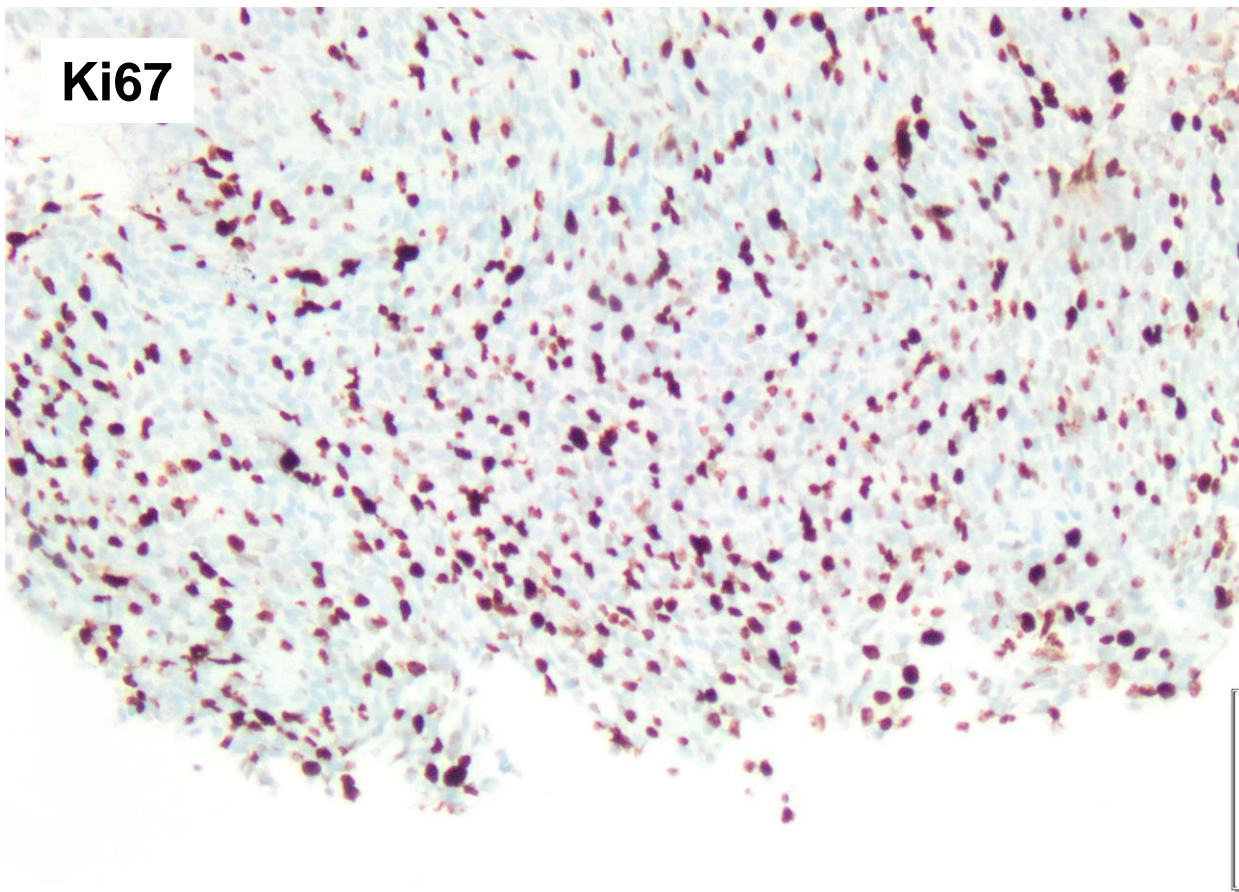




**CD99**



**Ki67**



## Kasuistik 23-21

Welche Zusatzuntersuchungen beauftragen Sie?

Welche Diagnose stellen Sie?