

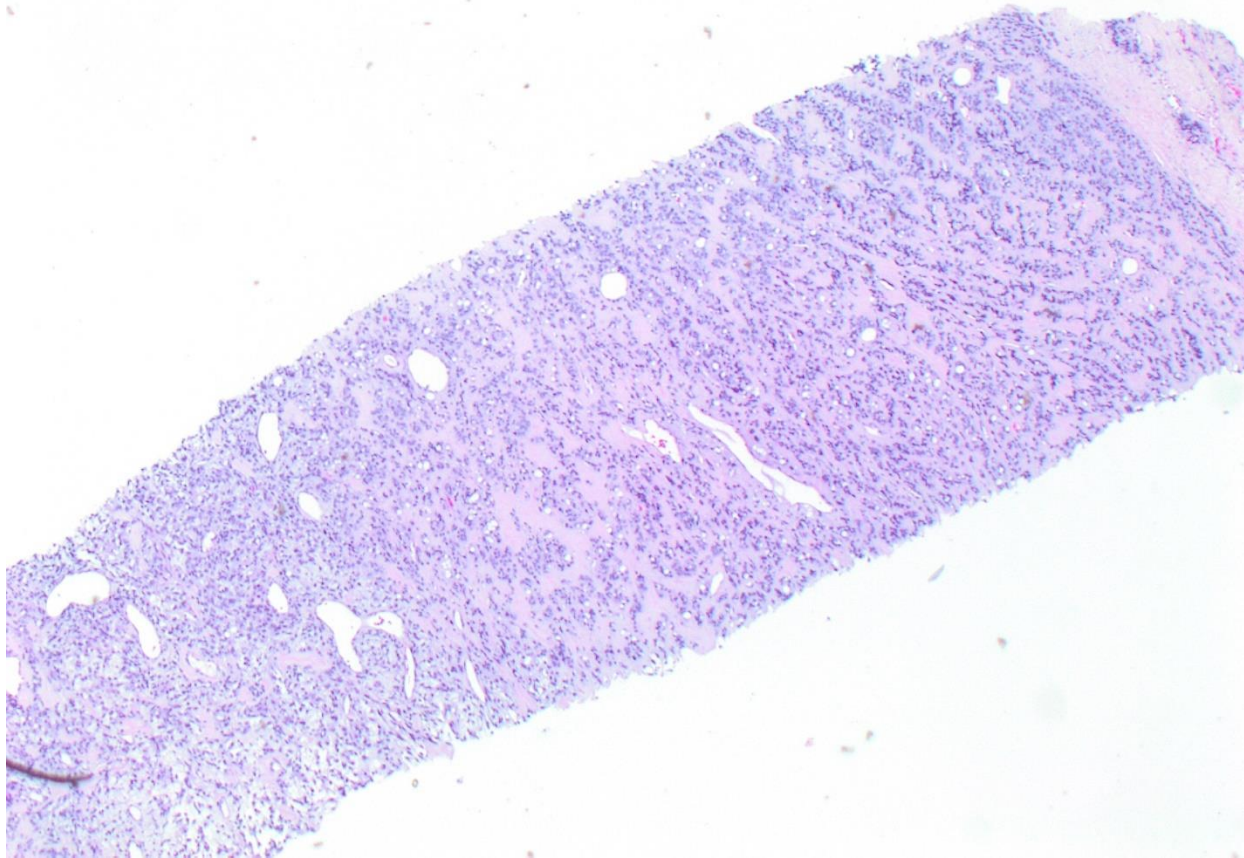
Kasuistik 25-21

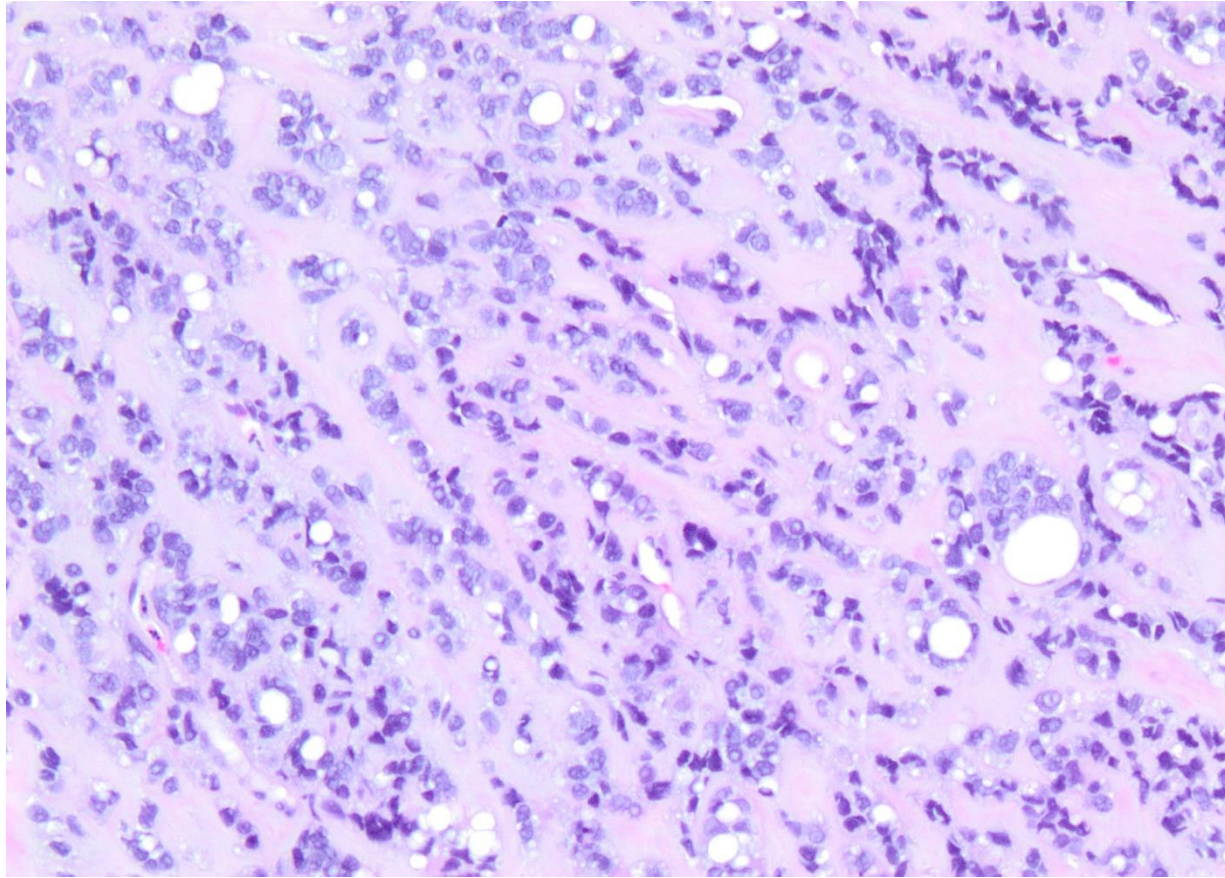
65-jähriger Mann

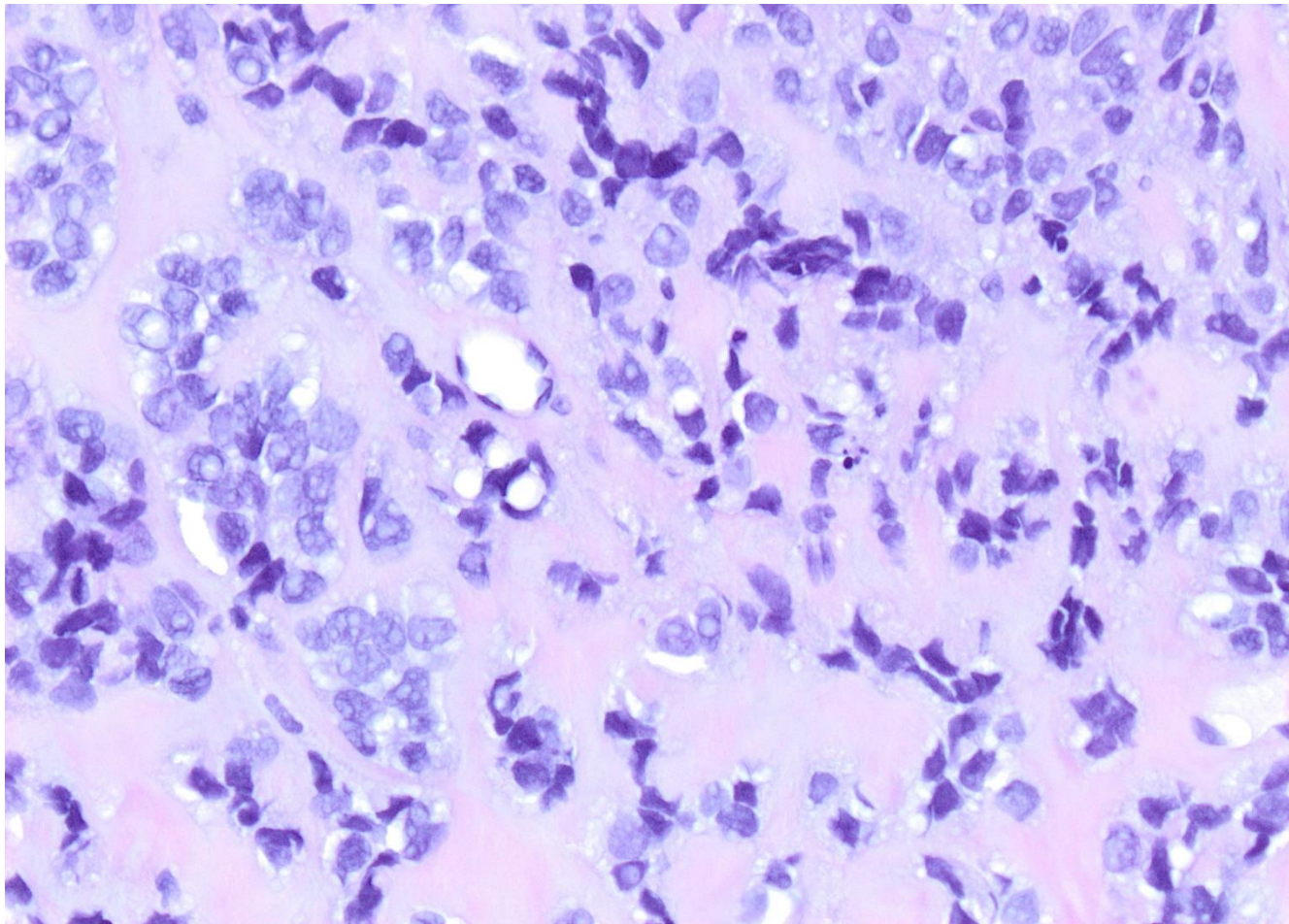
5 cm großer solider Tumor

im subkutanen Fettgewebe

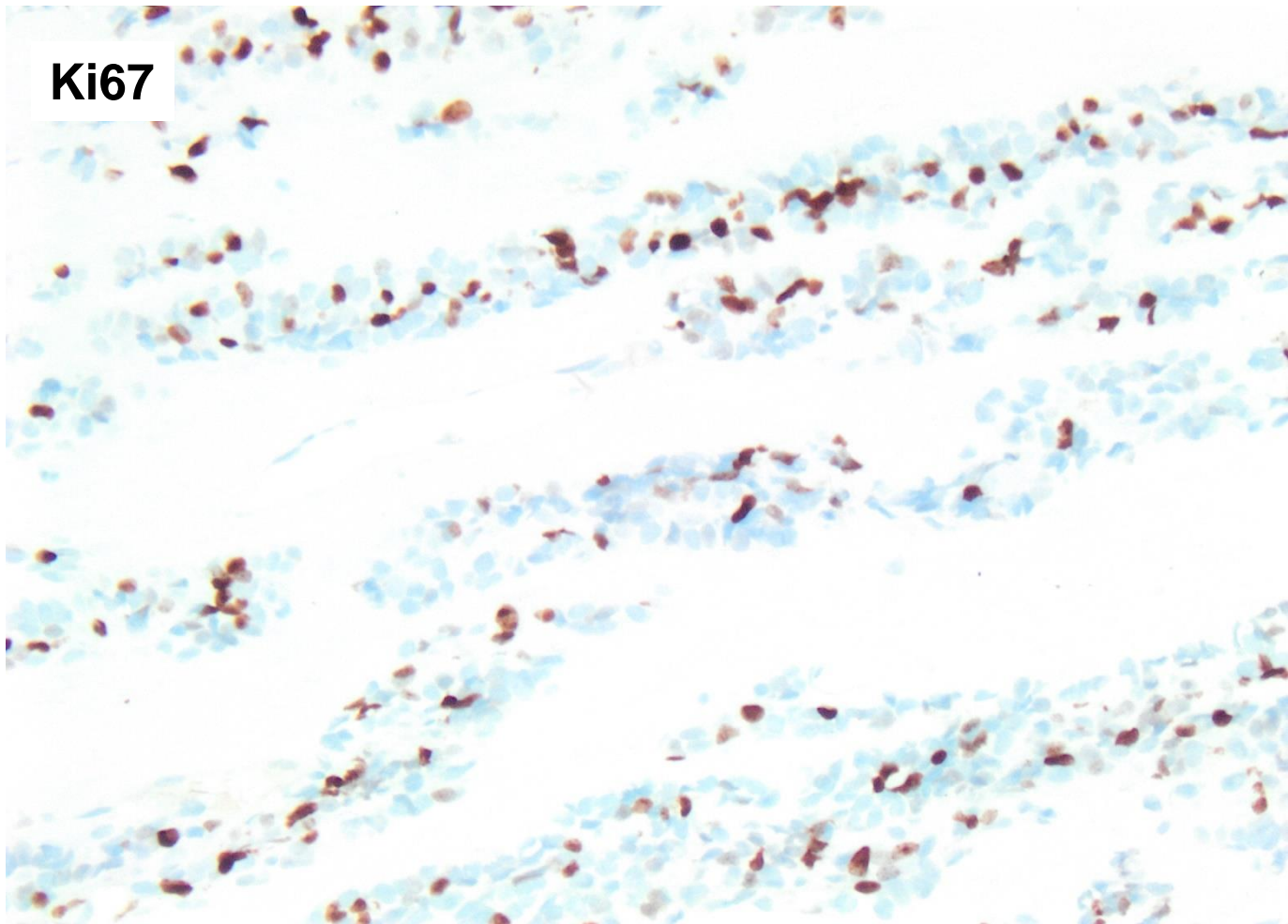
rechter Unterschenkel







Ki67



Kasuistik 25-21

Welche Zusatzuntersuchungen beauftragen Sie?

Welche Diagnose stellen Sie?